

# JSP

## JOURNAL OF SURGERY PAKISTAN INTERNATIONAL

### EDITOR IN CHIEF EDITOR ASSOCIATE EDITORS

F.U.Baqai  
Abdul Aziz  
Asadullah Khan  
Abdul Moeed Kazi  
Jamshed Akhtar  
Azhar Husain  
Irshad Waheed  
Mohammad Shamim  
Masood Javaid  
Saghir Ahmed  
S.A.Jilani  
Rashid Ahmad Choudhry  
Zahida Baqai

### EDITORIAL BOARD

### EDITORIAL CONSULTANTS

#### AUSTRALIA BANGLADESH

Earl R.Owen  
Ahsanullah Chowdhury  
M.Kabiruddin Ahmed  
Humayun Kabir Choudhury

#### EGYPT INDIA

Reffat Kamel  
Tehemton E.Udwadia  
Ahmed Abdul Hai

#### JORDAN NEPAL

I.K. Dhawan  
Ibrahim Bani Bani  
I.B. Thappa  
A.K.Sharma  
Dharuba Mudavari

#### REPUBLIC OF MALDIVES SRI LANKA U.K.

Imteyaz Mohsin  
A.P.R. Aluwihare  
John Hadfield  
J.S.P. Lumley  
Essa Kazim  
Abdullah Jan Jaffar  
Adib ul Hasan Rizvi  
Changez Hakim Khan  
Faiz Mohammad Khan  
Ghulam Ali Memon  
Ijaz H. Aqeel  
Inamul Haq Shami  
Jan Mohammed Memon  
Muhammad Iqbal  
Moizuddin  
M.Younis Khatri  
M. Naeem Khan  
Nazir M.Kazi  
Shah Nawaz Shah  
Sikander Shaikh  
Syed Azhar Ahmed  
Tariq Saeed Mufti  
Tipu Sultan  
Z.K.Kazi  
Zafarullah Chaudhry

#### U.A.E. PAKISTAN

Published by: Prof. Abdul Aziz for  
Prof. F.U. Baqai, Baqai Postgraduate  
Medical Institute, IIC, 1/12, Nazimabad,  
Karachi

Address for correspondence: Col.  
(Retd.) Masudul Haque, Executive  
Secretary, Surgical Publications, c/o  
College of Physicians & Surgeons  
Pakistan, 7th Central Street Defence  
Housing Authority Karachi, Tel. 5890029 &  
Fax: 5887333

Subscription rates: Per copy-in  
Pakistan Rs.100/= in SAARC countries  
U.S. \$20, in other countries U.S.\$30,  
Annual- in Pakistan Rs.300/= in SAARC  
countries US \$ 60, in other countries  
U.S.\$90.

Layout by : Aleemuddin Siddiqui.

### EDITOR'S NOTE

Pancreatic Carcinoma Irshad Waheed 1

### ORIGINAL ARTICLES

Experience with severe forms of Amniotic  
Bands of the limbs and review of  
literature. Faizah Naheed Bhatti, Amna  
Nasir and M. Naeem-uz-zafar Khan 2

Incidence of carcinoma in nodular goitre.  
Salim Soomro, Shah Zaman,  
Nusrat Anis, Anis Subhan  
and Majeed Balooch 6

Early experience of Laparoscopic  
Cholecystectomy at JPMC. Mir Zafar Ali, Rizwan Nasim,  
S.Sagheer Hussain Shah,  
Shahid Rasul, Rasheed A. Ch.,  
and Irshad Waheed 8

The role of antioxidant-Emoxipine on  
Corneal conservation. R. Goundorova, I. Choroshilova,  
L.Ilatovskaia & S. Siddique (Russia) 10

Road Traffic Accident Injuries in  
Children Shabbir Hussain, Ghulam Ali,  
Mohammad Aslam, Irfan Qureshi,  
Rafiq Khanani and Sanaullah 11

Surgical Approach for Hepatic Hydatid  
Disease G. Asghar Channa and Ahmar  
Ali Shah 13

Primary Varicose Veins—  
Experience at Military Hospital Dilawar Mehmood and  
Irfan Ahmad 15

### CASE REPORTS

Late onset oesophageal perforation due  
to gunshot injury of chest: successful non  
operative management in a young child. Asad I. Mian, Saima H. Khan  
and M. Naeem-uz-Zafar Khan 17

Phytobezoar of small intestine. Abdul Sattar Memon, Jan  
Mohammad Memon and  
Abdul Ghani Soomro 21

Congenital lobar emphysema. Jamshed Akhtar, Zakauallah  
Waqasi and Abdul Aziz 23

Bilateral renal agenesis in parasitic twins  
with features of Potter's syndrome: A  
case report and review of literature. Amana Nasir, Faizah N. Bhatti,  
Farah Khan, Amjad Chaudhry  
and M. Naeem uz Zafar Khan 25

Acute Intermittent Porphyria Simulating  
Acute Surgical Abdomen Faisal Ahmed, Jamal Ara, Rukhsana  
Sattar and Shabeer Hussain 29

### BOOK REVIEW

Laparoscopic surgery in developing  
countries by Dr. T.E. Udwadia (India) Irshad Waheed 31

IRSHAD WAHEED  
JOURNAL OF SURGERY  
PAKISTAN  
KARACHI

# OBITUARY

## PROF. A. RAHIM

**P**rof. A. Rahim, the pioneer orthopaedic surgeon of Pakistan expired on 31st March 1995. May Almighty Allah bestow His blessings on him.

Prof. A. Rahim was born on 1st February 1915. He graduated from King Edward Medical College, Lahore in 1941 and joined Punjab Medical Services. From 1943 to 1947 he served the Indian Army in a hospital in Asam & Burma dealing with battle casualties. Prof. A. Rahim went to UK for post graduate studies, got F.R.C.S. in General Surgery in 1951, and M.Ch. Ortho from Liverpool in 1952. On his return from UK in 1953, he was appointed as Asstt. Prof. in Dow Medical College and Orthopaedic Surgeon in Civil Hospital, Karachi. He was promoted to Professor of Orthopaedic Surgery in 1964 and was appointed Medical Superintendent of Civil Hospital in 1966.



His work was not only in surgery of trauma, but also in orthopaedics like surgery of spine, hip, knee and hand. He was awarded Tamgha-e-Quaid-e-Azam twice by the Government of Pakistan.

In 1985 Prof. Rahim founded a hospital called the Orthopaedic and Medical Institute (OMI) in the private sector at his private clinic "The Clinic".

Prof. Rahim was a very strict disciplinarian. He used to follow rules and regulations himself and expected others to do the same. He continued his disciplined life even after retirement. He was always seen in the premises of hospital early in the morning caring for the birds and garden, which he loved so much.

## PROF. FAZAL ELAHI

**P**rof. Fazal Elahi, Professor Emeritus, CPSP, one of the pioneers of medical education in Pakistan and an eminent surgeon of Pakistan, died in Chicago, USA on January 2, 1996 (may God bless his soul).

Before joining the Department as an Honorary Director, he was Prof. of Surgery at Dow Medical College & Civil Hospital Karachi for a good number of years. He was also an active member and President of the Society of Surgeons Pakistan, Karachi Chapter. Prof. Elahi joined the Department of Medical Education at CPSP in January, 1985 and made laudable contributions in organizing regular training programs including workshops. He was also instrumental in the affiliation of the Department of Medical Education with the Department of Medical Education, University of Illinois, Chicago, USA.



He was instrumental in setting MCQ Bank at the College which led to the introduction of MCQs at the Fellowship examinations. He also contributed towards the introduction of Objective Structured Clinical Examination (OSCE) in certain examinations of the College. His monograph on OSCE is still being used in workshops at various centres.

## **PANCREATIC CARCINOMA: WHERE DO WE STAND TODAY**

**P**ancreatic pathology in general, and carcinoma in particular has traditionally been shrouded in mystery. Placed as it is in a relatively inaccessible and obscure position in the retroperitoneal region, it arrived late in medical diagnostic literature. Diagnostic methods helpful in the diagnosis of pancreatic pathology have arrived on the scene only comparatively recently. As a result, treatment methods too have lagged behind in development and general acceptance, as compared to other parts of the digestive system.

The first resection for Pancreatic carcinoma was performed in the early forties by Whipple and others. It was followed by other cases, with a variable mortality and morbidity after surgery. The biggest problem at that time was in knowing which tumours were malignant, needing radical procedures and which were benign, requiring limited procedures only. This problem has been solved to a large extent today by better pre-operative assessment and the availability of per-operative frozen section facilities.

Although Pancreatic resections were being done from the 1920s onwards, these procedures were confined to major centres in the more advanced countries. In a large majority of cases around the world, for a long time, pancreatic carcinoma was being managed palliatively with various biliary-enteric bypass procedures. These had good short term effects, but as expected, poor long term survival rates. The situation has now improved enormously, at least in cases of pancreatic head carcinomas.

This improvement has been achieved by excellent diagnostic imaging techniques including ultrasound, CT Scans, MRIs and recently developed Magnetic Resonance Cholangio-Pancreatography (M.R.C.P.). All these techniques are non-invasive, rendering invasive methods like P.T.C. or E.R.C.P. unnecessary in most cases. This has helped in greatly improved understanding of the importance of pre-operative preparation, including physiotherapy and nutrition etc. and better pre-operative management by anesthesiologists. The greatly improved post-operative care in surgical I.C.U.s, easy availability of frozen section facilities and introduction of newer surgical techniques, like the pylorus preserving resection etc. has brought down considerably the mortality of Whipple's procedure for pancreatic head carcinoma. The figures for periampullary carcinoma, which should be classed together with pancreatic head tumours as a clinical entity, are even better.

However, the prospects for malignancies of body and tail of the pancreas remain depressingly low. This is basically due to delay in presentation of these cases. Symptoms do not appear early on and problems that arise are symptomatically treated by the attending doctors after labelling the problem as dyspepsia, indigestion or irritable bowel. Many of the patients present with maturity-onset diabetes mellitus. Occasionally, the first indication that something is wrong is the occurrence of secondaries; Troisier's Lymph nodes in the supraclavicular region are often seen. A patient presented to me with a subcutaneous lump in the scalp which turned out to be a pancreatic secondary.

What is therefore required, in the light of our knowledge is that a high index of suspicion should be kept for pancreatic tumours. Full use of modern day investigative techniques should be made in cases where there is a strong likelihood of existence of these tumours, early surgery is mandatory, with a standby frozen section facility if possible.

**Irshad Waheed**

# EXPERIENCE WITH SEVERE FORMS OF AMNIOTIC BANDS OF THE LIMBS AND REVIEW OF LITERATURE

FAIZAH NAHEED BHATTI\*, AMNA NASIR\*, M. NAEEM-UZ-ZAFAR KHAN\*\*

## ABSTRACT

*Amniotic bands are curious congenital constriction bands which may involve any organ or tissue in the body. The most plausible theory is considered to be an early rupture of the amnion which results in the formation of fibrous bands. These bands may entangle any organ, but when they occur in limbs, they produce different degree of injury distal to the site of constriction. In this article, amniotic bands afflicting the limbs have been studied. The results of surgical management are assessed and review of literature is presented.*

**KEY WORDS:** Amniotic bands, autoamputation, Congenital constriction rings.

## INTRODUCTION

Historically many authors have referred to amniotic bands with various names. These include "Annular Bands", "Constriction Band Disruption" and "Ring Constriction", as well as the more obscure terminologies such as "Streeter's Bands" and "Simonart's Bands". Amniotic band formation is thought to occur due to disruption process and results in destruction of previously formed normal element of the fetus<sup>2,3</sup>.

## MATERIALS AND METHODS

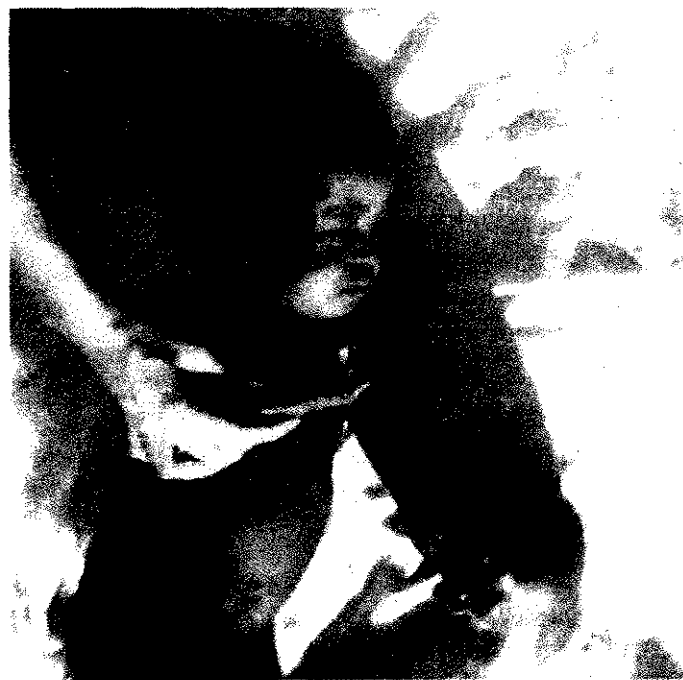Five cases of amniotic bands in children, who presented with severe sequelae of different nature from January 1987 to April 1996 were selected. For the present study less severe cases with isolated abnormalities are excluded. Age, sex, anatomical regions involved and the presenting abnormalities distal to the constricting bands were noted pre-operatively. The results after reconstructive surgery i.e. excision of the constricting band and multiple Z-plasties, were assessed and the resolution of pathological changes that were present before surgery, were studied.

## CASE REPORTS:

### Case No. 1

A 9 month old baby boy was admitted with multiple amni-

otic bands of toes of both feet resulting in autoamputations. There were distal syndactyly and partial amputations of the fingers of the right hand and circular amniotic bands on the fingers of the right hand and a circular amniotic band on the proximal left forearm causing massive lymphedema with elephant like skin (Fig.1).



**Figure 1** The right arm has jumbled fingers and autoamputations whereas the tight amniotic band of the left arm has produced massive lymphedema of the forearm and hand, so much so that only the nails with the tips of the fingers are showing.

\*Aga Khan University Medical College, Karachi.

\*\*Department of Paediatric Surgery, Children Hospital, Pakistan Institute of Medical Sciences, Islamabad, Pakistan.

All correspondence to:

Prof. M. Naeem-uz-Zafar Khan, Department of Paediatric Surgery, Children Hospital, Pakistan Institute of Medical Sciences, Islamabad.

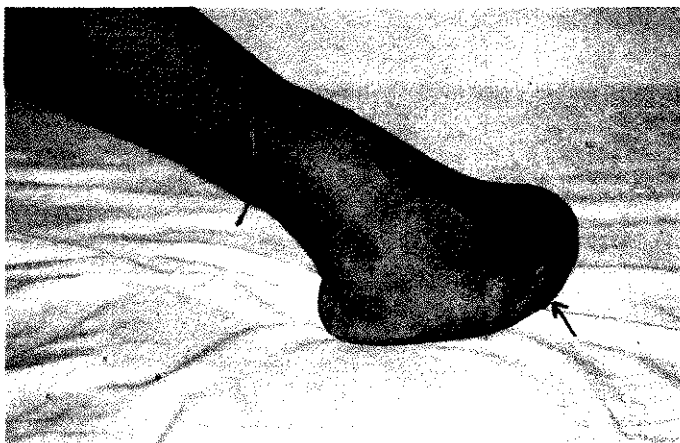The fingers had become engulfed within the swelling. The right hand function was compromised due to jumbling of the fingers and auto amputations, the left arm was totally non-functional. Division of the band on the left with multiple staged z-plasties resulted in considerable resolution of lymphedema with much improved function of the left upper limb. (Fig.2).



**Figure 2** The same patient as in Fig no. 1 after staged surgical release and Z-plasties with considerable reduction in size and edema of the hand with fairly functional fingers and hand

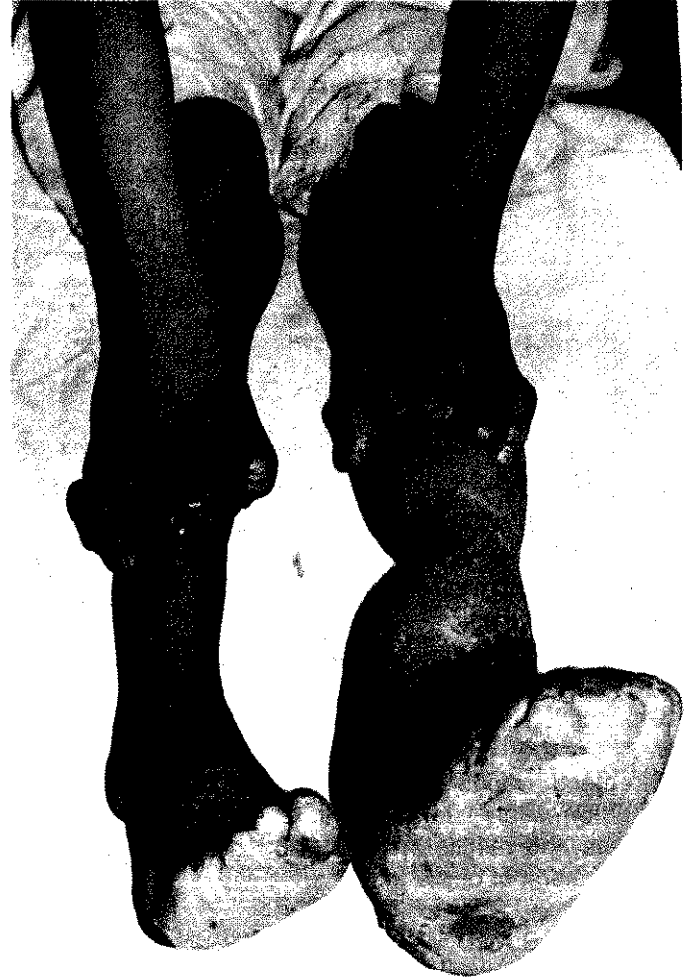### Case No. 2

A 10 year old boy was admitted with partial amniotic bands of a lower limb in the region of the thigh and leg. His toes had been amputated during intrauterine life. The tight band had resulted in edema, formation of callosities, trophic ulcers and anaesthesia of the foot (Fig.3).



**Figure 3** Post-operative appearance of patient in case no. 2 after six months of surgery (—). The edema has almost disappeared, although (—) callosities still persists. Padded soft shoe enabled him to walk comfortably.

Z-plasties with division and excision of the band which extended to the periosteum on the anterior surface of the tibia (Fig.4) followed by compression bandages and elevation of the limb allowed the foot to recover to an extent that the patient was able to walk freely.



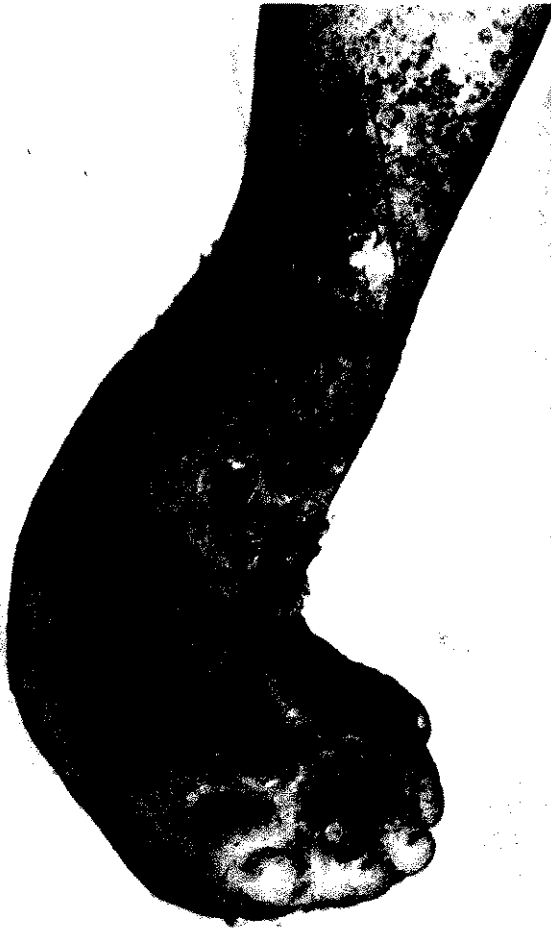**Figure 4** Case no. 2 demonstrates the effects of multiple amniotic bands resulting in autoamputations of the fingers and toes, jumbled fingers of the hand, massive elephantiasis like edema of the left foot, a cutaneous horn on the dorsum of the foot and hyperkeratotic skin with scaling.

### Case No.3

A two days' old baby boy was brought in with multiple circular cuts caused by amniotic bands around both thighs. One limb was considerably hypoplastic with equinovarus deformity. There were similar multiple amniotic bands around the fingers of his hands. The amniotic bands had resulted in complete disconnection of proximal and distal skin and the wounds were already heavily contaminated and infected. Distal circulation in this case was presumed to be sustained through the deeper structures. The wounds were thoroughly cleaned with antiseptics and all bands were divided and multiple z-plasties were performed. Postoperative progress was excellent. Because release of constriction was promptly performed, the long term results are expected to be much better.

**Case No.4**

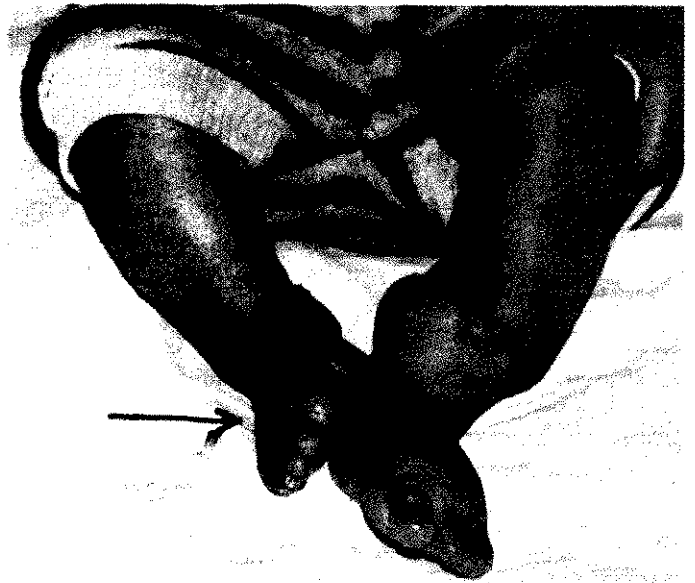
A boy of 13 presented with jumbled fingers with peripheral amputations. His right leg was grossly swollen due to chronic lymphedema with hyperkeratotic skin of the foot, scattered warty lesions, a large cutaneous horn on the dorsum of the foot and anaesthetic toes and feet, with a foul smelling contaminated fissured ulcer on the foot. Following z-plasties, the patient was kept recumbent with elevation of the affected limb. There was rapid reduction in lymphedema, considerable softening of the hyperkeratotic skin and healing of the fissured ulcer (Fig.5). Second stage z-plasties on the posterior side of the leg are now planned.



**Figure 5** After ten days of release of the amniotic bands with Z-plasties, incorporating the proximal healthy and distal edematous skin which resulted in rapid reduction in edema and healing of the fissured ulcer. Further Z-plasties on the posterior aspect of the leg are planned.

**Case No.5**

A baby girl of 9 months presented with bilateral amniotic bands of the distal one third of legs which had resulted in enlargement due to lymphedema of the right leg and talipes equinovarus of the left leg. She was treated with excision of the bands, multiple z-plasties and elongation of the tendo Achilles on the left side to correct the equinus deformity.



**Figure 6** Two months after surgery edema of the limb has subsided and the equinus deformity (—→) on the right foot has also been corrected by elongation of the tendo-Achilles and post capsulotomy of the ankle joint.

Because surgery has been performed at an early age, we expect future development of her limbs should be good (Fig. 6).

**DISCUSSION**

Estimates of the incidence of this condition ranges from 1 in 5000 to 1 in 10,000 and over 600 cases have been reported. No sex predilection has been observed<sup>4</sup>. Although many attempts have been made to discover a genetic alteration, it has not yielded any conclusive evidence. Most likely theory is that of obscure environmental (exogenous) influences that predispose to disruption of the placental layers leading to spontaneous amniotic rupture<sup>1,5</sup>. There has been one case report where amniocentesis done with a large needle predisposed to amniotic damage and subsequent rupture<sup>6</sup>. In one case series, 9500 patients were observed out of which amnion dysmorphism was observed in 30 cases by ultrasound. Pregnancy outcome was favorable in all cases, thus ultrasound visualization in early pregnancy has also been shown to have no adverse pregnancy outcome<sup>7</sup>. Familial clustering has been observed in one case of the Amniotic deformity, Adhesions, Mutilations (ADAM) complex<sup>8,9</sup>. Alternatively some form of germ cell defect or a defect in development of the tissues is also suspected<sup>3,9</sup>.

The ruptured amnion forms fibrous strands which entwine the fetus. Most characteristic is the presence of multiple fibrous strands of amnion extending from the placental insertion of the umbilical cord to the surface of the amnion denuded chorion or floating freely within the chorionic sac. Most often distal limbs of the fetus get strangulated,

as we have observed in our cases. Inadvertently the bands become permanently attached to the underlying soft tissue, which then must be removed by surgery.

Injury to the fetal parts may range from mere compression and ring strictures to intrauterine amputation. Extent of damage is determined by the duration and severity of the compression. Defects may be circular or transverse, and defects of varying tightness and depth may affect any or all layers of the skin and soft tissues beneath<sup>10</sup>. If the lymphatic as well as venous drainage is blocked, lymphedema and swelling of the dependent portion may be eminent. This edema should be differentiated from congenital lymphedema<sup>1</sup>. Amniotic bands also cause other pathologies like cleft lip, encephalocele etc<sup>11</sup>.

Mild to moderate vascular insufficiency of the developing limb bud causes nutritional depletion, leading to underdevelopment and a hypoplastic limb. But this may be initially masked by the gross lymphatic swelling. Severe arterial obstruction will eventually cause ischemia and necrosis of the dependent limb. The ultimate outcome is intrauterine amputation. Nerve compression may give rise to neuropathy, as well as distal anaesthesia. Ischemic insufficiency can lead to trophic ulcers, Callosities and horns.

Constriction bands often bind fingers together during the process of their separation. This leads to pseudosyndactyly<sup>2</sup>. Pseudosyndactyly, also known as jumbled fingers, is distal in nature, whereas primary syndactyly is proximal. Sometimes talipes equinovarus can also occur due to these bands as seen in case No.5.

Severe cases are usually associated with raised levels of alpha-fetoprotein and acetylcholinesterase in the amniotic fluid. The anomalies usually result from exogenous influences<sup>5,9</sup>, but an observation in two members of a family suggests that genetic factors might operate in some cases<sup>9</sup>. As a rule the absent parts due to autoamputation are usually multiple, but rarely bilaterally symmetrical. Symmetrical cases are usually genetic in origin<sup>4</sup>.

The primary goal would be to relieve lymphedema, and restore normal circulation as soon as possible. The band is removed by plastic procedures, which then exposes the underlying constricted defect. This must be repaired by multiple Z-plasties<sup>12</sup>. Conjoined fingers must be detached and skin grafts may be necessary to provide proper shape. Criteria for management should include degree of compression, and loss of function. By and large general rule is early correction by plastic and orthopaedic procedures in order to allow the child maximal use of his hands and feet. Generally the prognosis of such patients is good.

## REFERENCES

1. Welch; Randolph; Ravitch; O'Neil; Rowe. Paediatric Surgery Vol 2; 4th ed. Year book Med.publishes 1986.
2. Behrman, R.E.; Kliegman,R.M.; Nelson,W.E.; VaughanIII,V.C. Nelson Textbook of Paediatrics, 14th ed. W.B. Saunders Comp, 1992.
3. Pers,M. Congenital absence of skin: Pathogenesis and relation to ring constriction. Acta.Chir.Scand. 1963; 126:388.
4. Goodman,R.M; Gorlin,R.J. Amniotic Band Disruption Complex. The Malformed Infant and Child-An Illustrated Guide. Oxford University Press, 1983.
5. Neuhauser,G; Sitzman,F. ADAM Complex- maxillofacial abnormalities and abnormalities of the extremities caused by amniotic strangulations. Dtsch- Zahnrtzl-z. 1979 Jul;34(7) : 546-50.
6. Weinzwieg,N. Constriction band induced vascular compromise of the foot: Classification and management of the "intermediate stage of constriction ring syndrome. Plas Reconstr Surg 1995; 96(4) :972-7.
7. Zimmer,E.Z; Bronshtein,M. Ultrasound observation of amnion dysmorphism at 14.5-16 weeks. prenatal. Diagn 1995 May;15(5) : 447-9
8. Keller,H; Neuhauser,G; Durkin-Stamm-MV; Kavaggia,E.g; Schaff,A; Sitzman,F ADAM Complex- a pattern of craniofacial and limb defects. Am.J.Med.Gen. 1978;2(1) : 81-98.
9. Streeter,G,L. Focal Deficiencies in fetal tissues and their relation to intrauterine amputation. Contrib.Embryol(Carnegie Institute Washington) 1930; 22:1.
10. Higginbottom,M,C; Jones,K,L; Hall,B,D; Smith,D,W. The amniotic band disruption complex: timing of amniotic rupture and variable spectra of consequent defects. J.Peadiatr. 1979 Oct;95(4) :544-9.
11. Miyajima,K; Natsume,N; Kawai,T; Tizuka,T. Oblique facial cleft, cleft palate, and supernumerary teeth secondary to amniotic bands. Cleft.palate.Craniofacial.J. 1994 Nov; 31(6) : 483-6.
12. Weinzwieg,N; Barr,A. Radial, ulnar admedian nerve palsies caused by a congenital constriction band of the arm: single stage correction. Plast.Reconst.Surg, 1994 Nov;94(6) : 872-6.

# INCIDENCE OF CARCINOMA IN NODULAR GOITRE

SALIM SOOMRO, SHAH ZAMAN, NUSRAT ANIS, ANIS SUBHANI AND MAJEED BALOCH

## ABSTRACT

*In six years from Jan 1990 to Dec 1995, 369 (90 males and 279 females) euthyroid patients with goitre were operated in Surgical Unit-II, JPMC Karachi. On technitium 99 Isotope Scan 175 were solitary nodules and 194 were multiple nodular goitres. All these patients were clinically and biochemically euthyroid. On Biopsy 15.52% solitary nodules and 11.94% multinodular goitres were malignant; over all incidence of malignancy was 13.6%*

**KEY WORDS:-** Carcinoma in Nodular Goitre

## INTRODUCTION

Palpable Multinodular or Solitary nodule of thyroid gland remains a common reason for referral of a large number of patients to both Surgeons & Physicians. On clinical examination, Technitium 99 Isotope Scan and ultra sonography diagnosis of solitary or multinodularity is made with final confirmation at surgery and on histopathology.

Much controversy exists over appropriate diagnostic and therapeutic management of nodular goitre. This is compounded by the facts that thyroid nodules are relatively common, malignancy is also not very rare and a well differentiated thyroid cancer generally runs a very indolent course.

## PURPOSE OF STUDY

To determine the incidence of malignancy of thyroid in solitary and multi nodular goitres operated in Surgical Unit-II, JPMC Karachi, a major tertiary hospital of the country.

## MATERIAL AND METHODS

All euthyroid patients admitted to Surgical Unit-II from Jan 1990 to Dec 1995 were included in the study. All the patients had complete clinical examination, hormonal assay (Serum T3, T4 & TSH) and radioisotope (Tc99) Scan. FNAC was done on all the solitary nod-

ules before surgery. Partial thyroidectomy was done in multi nodular goitres and lobectomy was done in solitary nodular goitres. All the operated specimens were subjected to histopathology.

## RESULTS:

In the 6 years study of the 369 euthyroid patients, 75.7% were females and 24.3% were males. Maximum number of patients were of the age group of 30-40 years. (Table I) Solitary nodular goitre were 175 and 194 were multi nodular.

**Table-I**  
**Sex Distribution**

Age of Patient (years)	Number of patient	%
10 - 20	29	7.8
21 - 30	60	16.2
31 - 40	143	33.7
41 - 50	106	23.9
51 - 60	20	5.4
61 - 70	11	3

Incidence of carcinoma was 15.52% in solitary nodular and 11.94% in multi nodular goitres. Overall incidence of carcinoma in euthyroid nodular was 13.6%. Table II

All correspondence to:  
Prof. Majeed Baloch  
Surgical Ward II, J.P.M.C, Karachi



Table-II

## Biopsy Findings of 369 cases

Nodular Goitre	Papillary Carcinoma	Follicular adenoma	Medullary carcinoma	Undiffer entiated	Lymphoma
300	26	24	07	05	02

## DISCUSSION:

In our study the incidence of thyroid carcinoma in nodular goitre is significantly higher. A varying incidence of 8.1% to 20% carcinoma have been reported by different authors in solitary nodules.<sup>3,4,9</sup> Whereas in multi-nodular goitre the incidence is comparatively less.<sup>2</sup> Hinton and Lord<sup>7</sup> have reported unexpected malignancy occurring in 7.6% cases. 7.5% incidental Carcinomas have been similarly reported by Koh and Chang.<sup>8</sup>

In a series of 192 cases, Brower<sup>1</sup> has reported a very high incidence of carcinoma, malignancy was found in 11% of multi nodular group and 24% of solitary adenoma group (an overall incidence of 17.1%).

The problem of thyroid Carcinoma revolves around nodular goitre and a non exhalant approach is not justified.<sup>5,6</sup> The high incidence of carcinoma occurring in nodular goitre (solitary and multiple adenomata) justifies the contention that surgical attack is more imperative in thyroid nodules.<sup>1,10</sup>

## REFERENCES:

1. Brower, B. Arthur: Relationship of nodular goitre to thyroic carcinoma, Ann. W. Med. Surg., 1949; Vol 3, 11, PP 395, 397.
2. Clark, H. ORLQ: Current surgical diagnosis and treatment 9th edition, 1991, p 267-275.
3. Fassihuddin, Q.: The solitary throid nodule: Fast and fallacy. Dissertation, 1982; 6.
4. Friedman, M., Toriumi and Mehmood, M.G.: Diagnostic imaging techniques in thyroid cancer, Am. J. Surg., 1985; 155:215-220.
5. Gagel, Andreas Graer, Friedhelm: Carcinoma of thyroid. Endocrinology and Metabolish. Clin. N. Amer., 199; 19:3-613-621.
6. Gharih and Goellner, J.R.: Evaluation of nodular thyroid disease. Endocrinology and Metabolism. Clin. N. Amer., 1988; 17:511-526.
7. Hinton, J.W. and Lord, J.W., Jr.:Surgery indicated in all cases of nodular goitre, toxic and non toxic. J.A.M.A., 1945:129:605-606.
8. Koh and Chang:Carcinoma in multi nodular goitre. Br. J. Sur., 1992; 79:266-267.
9. Matheson, N.:The thyroid gland. Bailey and Love's Shei practice of Surgery. Twenty- first edition, 1991; pp 733-765.
10. Wanebo, H.J. et. al.:Thyroid cancer, some basic considerations. Am. J. Surg., 1981; 147:471.

# EARLY EXPERIENCE OF LAPAROSCOPIC CHOLECYSTECTOMY AT J.P.M.C

MIR ZAFAR ALI, RIZWAN NASIM, S. SAGHEER HUSSAIN SHAH,  
SHAHID RASUL, RASHEED A. CH., IRSHAD WAHEED

## ABSTRACT

*The application of minimal invasive surgical technique for the removal of gallbladder has emerged as the preferred method of treating symptomatic gallstone disease. The objective of this study is to find out the complications, conversion, reason for conversion and hospital stay of 127 laparoscopic cholecystectomies performed over a period of 16 months at JPMC from June 1994 to October 1995. As an early experience one hundred and eleven were successfully operated laparoscopically and 16 converted to open laparotomy. Average duration of stay after successful laparoscopic cholecystectomy was 4 days.*

**KEY WORD:** *Laparoscopic Cholecystectomy, Early Experience*

## INTRODUCTION

With the availability of facilities of operative laparoscopy at JPMC, this study was designed to evaluate the reasons for conversions, complications, hospital stay during the early period. Now a days most of the patients having symptomatic gall stone are treated with laparoscopy. Laparoscopic gallbladder operations are associated with less morbidity than conventional open cholecystectomy.

## PATIENTS AND METHODS

This is a sixteen month retrospective study of an early experience of laparoscopic cholecystectomy carried out in two surgical units of JPMC. This study is divided into two equal halves - each of 8 months duration. Six consultant surgeons operated upon the cases. Patients were admitted through the out-patient clinics, after confirmation of diagnosis of cholelithiasis. All the cases were operated under general anaesthesia. Prophylactic first generation cephalosporin (Ceporex) was given intravenously at the time of induction of anaesthesia.

## RESULTS

During 16 months period from June 1994 to October 1995, 127 cases were approached laparoscopically and cholecystectomy was performed. This study is divided into two equal halves, each of eight months duration.

All correspondence to:  
Dr. Mir Zafar Ali, Department of Surgery,  
Jinnah Postgraduate Medical Centre,  
Karachi.

In the first half 49 (38.5%) and in the second 78 (61.5%) cholecystectomies were performed laparoscopically. The mean operating time for laparoscopic cholecystectomies was 100 minutes in the first half and 72 minutes in the second half. Overall complication rate was 10.2% (13 cases) (Table I). Six cases (4.72%) were converted to open laparotomy in the first half, and 10 cases (7.87%) in the second half. Overall rate of conversion was 12.59% (16 cases). The reasons for conversion were adhesions, anatomical variations, hemorrhage, failure of equipment, carcinoma of gallbladder, common bile duct damage and empyema gallbladder (Table II,III). Mean hospital stay after successful laparoscopic cholecystectomies was 4.2 days and 6.3 days in converted cases (Table III).

**Table-I**  
**Complications**

	Laparoscopic Surgery
Wound Infection	3
Transient Jaundice	3
Biliary Fistula	2
Retained Stone in CBD	1
Surgical Emphysema	2
Intra Abdominal Collection	2

**Table-II****Ratio of conversion in both halves of laparoscopic cholecystectomy**

	1st Half	2nd Half
Laparoscopic Cholecystectomies	49 (38.5%)	78 (61.5%)
No. of Successful Lapcholecystectomy	43 (87.8%)	68 (87.2%)
No. of Conversion	06 (12.2%)	10 (12.8%)

**Table-III****Reasons for conversion**

Reasons for Conversion	Cases in 1st Half	Cases in 2nd Half
Adhesions	3	3
Hemorrhage	1	2
Anatomical Variation	0	2
Failure of Equipment	0	2
Carcinoma Gall Bladder	1	0
CBD Transection	1	
Emphyema Gall Bladder	0	1

**Table-IV****Hospital stay after surgery**

No. of Days	Successful Laparoscopic	Converted
1 Day	1	0
2 Day	17	0
3 Day	36	0
4 Day	19	6
5 Day	16	4
6 Day	9	1
7 Day	5	0
Above 7 Days	8	5
<b>Total</b>	<b>111</b>	<b>16</b>

**DISCUSSION**

Laparoscopic cholecystectomy is rapidly becoming the treatment of choice for symptomatic gallstone disease.<sup>1,2</sup> because a successful laparoscopic operation is associated with less morbidity than conventional one but it might be associated with high rate of serious complications, especially bile duct injury and damage to gut during trocars entry<sup>3</sup>. Besides all this it is an expensive procedure and lot of expertise and experience is required to perform this operation. The main drawback with this technique is difficulty in hand-eye coordination, and the inability to feel the structures. In addition, laparoscopic cholecystectomies might be associated with high rate of serious complications, especially bile duct injury & damage of gut with trocars entry<sup>4,5</sup>.

Our experience of 127 laparoscopic cholecystectomies have convinced us that successful outcome of laparoscopic cholecystectomies is dependent upon proper patients selection, meticulous techniques and attitude to convert to open if needed. In our study, the reason for conversion was highest in cases with adhesions and due to hemorrhage followed by anatomical variations in two cases. Preoperative failure of equipment was a reason for conversion in two cases. A case was opened because of bile duct damage by diathermy and another due to empyema gallbladder (Table III). Hospitalization and recovery time was significantly shorter in successful laparoscopic operation with the benefit of minimal trauma but comparing with converted cases, there was marked difference (Table IV). We found that this technique should be performed with fully equipped theatre with stand-by for open conversion and surgeon should have an adequate experience in open biliary surgery as well as expertise in the technique of laparoscopy.

In this study the results do not compare well with those in published literature perhaps because it was an early learning experience.

**CONCLUSION**

In the light of the present study we believe that surgeons should rationalize the provision of laparoscopic surgery among themselves and should be careful in the selection of the patients. Considering obvious benefit of laparoscopic cholecystectomies, we have to measure its drawbacks and it seems appropriate to perform careful studies in all centres where laparoscopic surgery is being performed. Our results are not comparable with the international study of early experience because we are in the "learning curve".

## REFERENCES

1. Macntyne IMC, Wilson RG. Laparoscopic Cholecystectomy Br. J. Surg. 1993 8:552-9
2. Grace Pa, Qureshi A, Coleman J. et al. Reduced post operative hospitalization after laparoscopic cholecystectomy Br. J. 1991, 78:160-2
3. Moosa AR, Easter DW, Van Sonnerberg E, Casola G, D Agostino H. Laparoscopic versus open Cholecystectomy; hospitalization, sick leave, analgesia and trauma responses Br. J. 1992, 215:203-8
4. R. J. C. Steel, K. Marshall, M. Lang and J. Doran. Introduction of laparoscopic cholecystectomy in a large hospital independent audit of the first 3 years Br. J. 1995, 82:968-971
5. A. J. Mc Mohan, G. Fullarton, J. N. Baxyer and P. J. O. Dwyer. Bile duct injury and bile leakage in laparoscopic surgery Br. J. 1995, 82:307-313
6. G. Crosthwaite, T. Chung, P. Dunkely, S. Shine and A. Cuschiexi. Comparison of direct vision and electronic two and three dimensional display system on surgical task efficiency in endoscopic surgery Br. J. 1995, 82:847-851
7. Stoker ME, Vose J, O' Mara P, Maini BS. Laparoscopic cholecystectomy A clinical and financial analysis of 280 operations Arch Surg 1992, 127:589-95

## ROLE OF ANTIOXIDANT-EMOXIPINE ON CORNEAL CONSERVATION

### (AN ELECTRON MICROSCOPY INVESTIGATION)

R. GOUNDOROVA, I. CHOROSHILOVA, G. BORDIOGOVA, , L. ILATOVSKAIA, S. SIDDIQUE,

We investigated the role of emoxipine in the structural preservation of two groups of corneas: 1. Control group where the preservation was completed on classical method of filatovs, where eye ball was refrigerated at +2°C to +4°C. 2. The experimental group, 0.5 ml to 0.7 ml emoxipine where injected into interior chamber.

All Chemical reactions in corneal tissue were slowed, by decreasing temperature, including free radical process, which play an important role in destruction of cell structure. That is why for blocking free radical process, in cornea we used a new antioxidant emoxipine.

After 3-8 days corneas fixed in 2.5% glutaraldehyde solution and dehydrate in alcohol.

With increasing degree of concentration ultra thin

slides were investigated under electron microscope (Tesla - 500). We used the method of total detachment of endothelium and impregnation of it by silver (Smolin's method) and investigated, under light microscope. We studied 25 human and rabbits' corneas.

Our morphological investigation showed that injecting emoxipine into the interior chamber of the eye, promotes preservation of the cornea especially for endothelial cells. These cells were intact as compared to control group, where many endothelial cells were deleterious, increasing the period of conservation to 6-7 days.

Experimental investigation showed that moist chamber refrigerated at +2°C to +4°C, slows down autolysis process. Injecting emoxipine into the interior chamber doubles the structural preservation as compared to the control group.

All correspondence to:  
Department of Ophthalmology,  
Reconstructive Surgery,  
Holmoltz's Institute of Eye Diseases,  
Moscow, Russia.

# ROAD TRAFFIC ACCIDENT INJURIES IN CHILDREN

SHABBIR HUSSAIN, GHULAM ALI, MOHAMMAD ASLAM, IRFAN QURESHI,  
RAFIQ KHANANI, SANAULLAH

## ABSTRACT:

*During one year (30th Nov. 92 - 1st Dec. 93), 104 cases below 15 years of age of Traffic Injuries reported to JPMC emergency room including 112 abrasions, 6 bruises, 82 laceration and 17 fractures. Nine cases were fatal, most due to head & neck injuries. Maximum no of fatal cases occurred in the early morning hours or late night.*

**Key Words:-** Road Traffic Accidents (RTA), Children Cause of death in RTA.

## INTRODUCTION

Road traffic accidents are public health problem and their magnitude has been recognized by the 27th World Health Assembly by concluding that a workable solution to this problem requires coordinated efforts of international agencies and organization, national, regional and local authorities and those of world citizenry.<sup>(1)</sup>

Road traffic accidents (RTA) are a leading cause of death among those under 30 years and account for a greater proportion of years of potential life loss than cancer and heart disease combined<sup>(2,3)</sup>. They involve bicycle, motor vehicles and animal carts in Pakistan.

## MATERIAL AND METHODS

This study was conducted at Jinnah Postgraduate Medical Centre (JPMC) from 30th November 1992 to 1st December 1993. In a period of one year, 104 children under 15 years of age reported at JPMC emergency room and accident department after road traffic accidents. After complete physical and necessary radiological examination, they were referred to specialized units for management. The data was collected on a proforma which included, name, age, sex, site of injury, type of injury (abrasion, bruise, fracture, amputation), out patient care and admission or death. An attempt was made to determine the injury responsible for death infatal injuries.

## RESULTS

During one year study 104 children under 15 years of age reported in E.R. There were 67 male(64%) and 37 female (36%), patients, with male to female ratio of 1:8:1. Nine (8.7%) cases, (5 male and 4 female) were fatal.

Abrasions were the most common type of injuries on more than one anatomical region of the body. (Table-I). The timing of the number of reported cases exhibits an interesting pattern. Majority of the cases reported between 12:00 Noon to 6:00 P.M. Only 5 cases were admitted for further observations, rest were discharged after administration of necessary treatment.

**Table-I**

Region	Pattern of injury				Total
	A	B	L/W	FR	
Upper Limb	18	0	5	4	27
Lower	35	1	19	10	65
Head & Neck	46	3	57	2	108
Chest	9	3	0	1	12
Abdomen	4	0	1	0	5
Total	112	6	82	17	217

No. of Patients = 104

A = Abrasion B = Bruise L/W = Laceration FR = Fracture

All correspondence to:

Dr. Ghulam Ali, Department of Forensic Medicine  
Sindh Medical College, Karachi.

## DISCUSSION

Road traffic accidents occur in every part of the world where automobiles are used. They are the leading causes of unnatural deaths around the globe.<sup>(4,6)</sup> Male predominance is reported in most of the series.<sup>(7,8)</sup>

In our series injuries of the lower limb (70.4% are more than those on the upper limb (29.6%). The lower limb is more prone to fracture being weight bearing and hit easily. Tibia is the most commonly broken bone in the lower limb. Elsewhere the pattern of injuries is almost the same.<sup>(9)</sup>

Maximum number of accidents occurred between 12:00 Noon and 6:00 P.M. (Table-II) It coincided with the peak schooling hours as the morning shifts come off and the afternoon shifts of most schools begin. It is therefore emphasized that reckless driving should be checked near school premises. Quite interestingly, the maximum fatalities occurred between 12:00 midnight & 6:00 A.M. They were mostly recorded near the airport, railway station and in those areas where marriage halls (public places of gatherings) are plentiful. The fatalities recorded near the airport or railway station can supposedly be due to the tendency of elders to take children to receive relatives arriving from out-station areas. While the fatalities reported from marriage hall areas can be explained by the presence of children at late night in these ceremonies and the location of marriage halls along main roads where heavy traffic moves with relatively high speed.

This study highlights the urgency of reducing accidental injury to children. Legislation and increasing public awareness by utilizing mass media can help in improving the present status.<sup>10</sup>

**Table-II**

### Time of arrival of Patients at the Hospital

Time Period	No. Of Cases
6:00 A.M. TO 12:00 NOON	26
12:00 NOON TO 6:00 P.M.	43
6:00 P.M. TO 12:00 NIGHT	28
12:00 NIGHT TO 6:00 A.M.	7
Total	104

## REFERENCES

1. Anos. avoidable epidemic. World Health (1975) P. 4 W.H.O. Geneva.
2. Anderson B. DW Finding from a major U.S. survey of patients hospitalized with head injuries. Public health Rep. (1983) 98(5) 475-8.
3. Aganga A.O: Epidemiology of RTA's in Zaria. Nigeria. J. soc. Health. Aug. 1983; 103(4): 123-6.
4. Jamieson E.G. The toll of road, Clinical aspects. B.M.J. (1966) 2:157.
5. Mc Farland RA: The epidemiology of motor vehicle accident. J.A.M.A. (1962), 180:189.
6. K.H. Neurological aspect of traffic accidents. Report of sub-committee of Canadian Neurosurgical Society. Canada Med. Association. J(167), 97, 1364.
7. Jinadu M.K. Epidemiology of motor cycle accidents in a developing country. J.R.S.H. (1984) 104(4):153-6.
8. Pless I.B. Accident prevention. BMJ(1991):303:462-4.
9. The National committee for injury prevention and control. Injury prevention; meeting the challenge. Am. J. Pre. Med.(1989):5:5-6.
10. Akhtar J., Aziz A. Trauma in children Pak J. Surg. 1994; 10:108-109.

# SURGICAL APPROACH FOR HEPATIC HYDATID DISEASE

G. ASGHAR CHANNA, AHMAR ALI SHAH

## ABSTRACT:

We reviewed thirty two patients of hepatic hydatid cysts treated surgically by us in the department of surgery J.P.M.C. Karachi, over a period of five years. The study was in relation to surgical procedure and complications resulting from the treatment and possible follow up of the patients. Ultra Sound scanning, being non invasive and sensitive investigation, was used regularly in follow up to assess the size of residual cavity and recurrence of the cyst<sup>1,4,5</sup>. Patients with biliary fistula and abscess formation with discharging tract were treated conservatively.

**KEY WORDS:** Liver hydatid disease, Surgery for hydatid disease, Complications of hydatid disease.

## INTRODUCTION

Many surgical techniques have been employed in the management of hydatid disease. Because of the fear of recurrence due to rupture and damage to the human tissue due to the scolicalidal agents, resection of the involved portion of liver has been advised, despite considerable morbidity and mortality<sup>13</sup>.

## MATERIAL & METHODS

Thirtytwo patients, operated during five years, were included in the study. All of these patients were operated by surgeons of a surgical unit. It was noticed that patients had come from all over the country, the majority being from Sindh and Baluchistan. Prospective investigation done included ultrasound, computerized tomographic scanning and Haemagglutination test. All patients were operated after assessment. Liver was approached through the subcostal or right para-median incisions. Nineteen out of 32 cysts (59%) were on the right side of the falciform ligament. Five (15%) cysts were seen in the region crossed by the falciform ligament. Cysts were identified by palpation and isolated with 10% saline soaked swabs. After aspirating, saline was injected and cyst evacuation was done. Difficulty was encountered while operating cysts on the summit of lobes and posteriorly seated cysts. If the cavity was larger it was filled with omentum

and stitched with chromic catgut. The cavities on the inferior aspect of the liver were drained by vacuum or dependent drains.

## RESULTS

In 10 (31.2%) patients mild to moderate spillage of fluid occurred. However no patient developed anaphylaxis. Seven patients developed fever after surgery. Radiology and ultrasound scanning revealed that three patients had pleural effusion, which responded to conservative measures. Four patients developed abscesses; they were treated by aspiration under ultrasound guidance.

Two patients developed biliary fistula remained in the hospital for 34 days and were followed-up in outpatient. The leakage progressively decreased and stopped over a period of two months. The longest follow-up in a few patients has been upto 5 years. Ultrasound scanning was repeated at six monthly intervals. Follow-up ultrasound scanning showed residual cavity or Hydrops.

Progressively decreasing size of the cavity was noticed and no hydatid sand was detected on subsequent Ultrasound examination.

## COMPLICATIONS

Spillage of hydatid fluid	10 patients (31.2%)
Pleural Effusion	3 patients (9 %)
Abscess	4 patients (1.2 %)
Biliary leak	2 patients

All correspondence to:  
Dr. G. Asghar Channa  
Deptt. of Surgery ,  
J.P.M.C.,  
Karachi.

## DISCUSSION

Liver, being the first filter for the echinococcus infestation, is a common site for the hydatid cysts formation. Many treatment modalities are being used to treat this condition.

Use of anti-helmenth drugs like albendazole and mebendazole has achieved partial success. These drugs are specially advocated in wide spread inoperable hydatidosis,<sup>15,11,9,12</sup> Ultrasound or computerized tomographic guided double percutaneous aspiration and injection technique (DPAI) is also used. The success of treatment has been claimed specially in uncomplicated hepatic hydatid cysts. The scolicidal agent is 95% alcohol or hypertonic saline<sup>7,8</sup>.

Surgery is the most common form of treatment for hepatic hydatid cysts. Omentoplasty, marsupialization, introflection, pericystectomy and hepatic resections are common techniques<sup>5</sup>.

In our series, surgical technique did not involve any major hepatic resection. There was no mortality. Two patients out of 32 had long hospital stay (34 days) who had biliary fistula. The fistula closed with conservative treatment. The abscesses were aspirated under ultrasound guidance.

## CONCLUSION

Without major liver resection hepatic hydatid cysts can be treated. Sclerosing cholangitis and anaphylaxis was not seen in this series of patients. Ultrasound scanning is a reliable diagnostic and follow up investigation. Biliary fistula heals spontaneously if no distal obstruction is detected.

## REFERENCES

1. Al-Habib-AA, etal. Hepatic Hydatid cysts: presentation and surgical management Yemen. J-R-Coll-Edin. 1992 Aug; 37 (4) 229-31.
2. Acumas-B; Rozanes-I; Celik-L; Minareci-O; Alper-A; Ariogul-O; Gokmen-E; Purely cystic Hydatid disease of the liver: treatment with percutaneous aspiration and injection of hypertonic saline. Radiology, 1992 Feb; 182 (2) : 541-3.
3. Akhan-O; Dincer-A; Gokoz-A; Sayed-I; Harlioglu-S; Abbasoglu-O; Eryilma-M; Basim-A; Baris-I. Percutaneous treatment of abdominal hydatid cysts with hypertonic saline and alcohol. An experimental study in sheep. Invet-Radiol. 1993 Feb; 28 (2) : 121-7.
4. Behus-A; Van-Heerden-J A. Surgical management of hepatic hydatid disease. HPB-Surg. 1992; 6(1) : 1193-7
5. Bilge-A; Sozuer-EM. Diagnostic and surgical treatment of hepatic hydatid disease. HPB-Surg. 1992; 6(1) : 57-64.
6. Demiraci-S; Eraslan-S; Andol-E; Bozatil-L. Comparison of the result of different surgical techniques in the management of hydatid cysts of the liver. World-J-Surg. 1989 Jan-Feb; 13 (1) : 88-90.
7. Giorgio-A; Tarantino-L; Francica-G; Mariniello-N; Aloisio-T; Sosia-E; Pierri-G. Unilocular hydatid cysts : treatment with U/S guided, double percutaneous aspiration and alcohol injection. Radiology, 1992 Sep; 184 (3) : 705-10.
8. Gori-S; Campatelli-A; Luchi-S; Palasдини-A; Savalli-E; Scasso-A. Cytology in the percutaneous treatment of hydatid cysts. A report of four cases. Acta-Cytol. 1993 May-Jun ; 37 (3) : 423-6.
9. Gocmen-A; Toppare-MF; Kiper-N. Treatment of hydatid disease in childhood with mebendazole. Eur-Respir-J. 1993 Feb; 6 (2) : 253-7.
10. Hai-AA; etal. Surgical treatment of hepatic hydatid cysts of liver. Indian-Med-Associ. 1991 Nov; 89 (11) : 313.
11. Lin-YH; Wang-XJ; Chen-YT. Preliminary observation of continuous albendazole therapy in alveolar echinococcosis. Chin-Med-J-Engl. 1991 Nov; 104 (11) : 930-3.
12. Meneghelli-UG; Martinelli-AL; Bellucdi-AD; Villanova-MG; Vellido-MA; Magro-JE. Polycystic hydatid disease (Echinococcus vogeli). Treatment with albendazole. JAnn-Trop-Med-Parasitol. 1992 April; 86 (2) : 151-6.
13. Ozmen-V; Igci-A; etal. Surgical treatment of hepatic hydatid disease. Can-J-Surg. 1992 Aug; 35 (4) : 423-7.
14. Todorov-T; Vutova-K; Mechkov-G; Georgiev-P; Petkov-D; Tonchev-Z; Nedelkov-G. Chemotherapy of human cystic echinococcus : comparative efficacy of mebendazole and albendazole. Ann-Trop-Med-Parasitol. 1992 Feb; 86 (1) : 59-66.
15. Todorov-T; Vutova-k; Mechkov-G; Lazarova-I. Experience in the chemotherapy of severe, inoperable echinococcosis in man. Infection. 1992 Jan -Feb ; 20 (1) : 19-24.
16. Vagianos-C; Pohydorou; etal. Successful treatment of post operative Ext. Biliary fistula. HPB-Surg. 1992; 6 (2) : 105-20 : discussion 120-4.
17. Xynos-E; etal. Hydatid disease of liver, diagnosis and surgical treatment. HPB-Surg. 1991 May; 4 (1) : 59-66 : discussion 66-7.



# PRIMARY VARICOSE VEINS: EXPERIENCE AT MILITARY HOSPITALS

DILAWAR MEHMOOD, IRFAN AHMED

## ABSTRACT:

*Eighty six patients were managed at two Military Hospitals in a two years period. Seventy eight patients were followed regularly. Majority of our patients were soldiers with a mean age of 32 years, long hours of standing being their occupational requirement. Saphenofemoral flush ligation was performed in all cases. Groin to upper calf long saphenous vein stripping was done in those with above knee varicosities and multiple stab avulsions were done for below knee varicosities. Recurrence occurred in 12 cases, the cause being inadequate initial operation.*

**KEY WORDS:** *Varicose veins, Saphenofemoral ligation, Surgical technique*

## INTRODUCTION

Incidence of primary varicose veins in our country is not known. Regarding pathophysiology of primary varicose veins, the concept is changing and now the fundamental defect is supposed to be primary defect in venous wall. A recent study has shown that reflux can occur in the presence of competent saphenofemoral valve.<sup>2,3</sup> Many surgical procedures have been proposed to deal with this disease. In military hospitals most of the patients are serving soldiers. This is the reason we are getting more patients with varicose veins than in civilian practice. The purpose of study is to review the present day surgical protocol for the treatment of varicose veins.

## MATERIAL AND METHODS

The study was conducted over a period of two years at Combined Military Hospitals Rawalpindi and Lahore. Eighty six patients were entered into this study of which eight patients were not available for regular follow-up. There were 6 female patients. The patients were mostly soldiers; the civilians who were treated with this disease belonged to the lower socio-economic group. Clinical assessment was the mainstay of the diagnosis. Ascending phlebography was done in 10 cases in which there was a clinical suspicion of deep vein thrombosis. For the purpose of study, the primary

varicose veins were described as dilated, lengthened and tortuous superficial veins with no obstruction to deep venous flow or any arterio-venous fistula. Saphenofemoral flush ligation was done in all cases. Groin to upper calf long saphenous vein stripping was done in those with above knee varicosities and multiple stab avulsions were done for below knee varicosities.

Post-operatively compression dressing crepe bandage was applied. Lower limbs were elevated for 12 hours to reduce hematoma formation and ensure hemostasis. Early ambulation was encouraged. Crepe bandage was continued for 2 weeks. The patients were told to report in outdoor after 2 weeks for initial evaluation and then after 6 weeks. Results were graded according to cosmetic appearance, relief of symptoms and recurrence of varicosities. The patients were then followed up for 6 months to a year.

## RESULTS

Of the 78 patients who were followed regularly there were 72 male and 6 female. Mean age was 32 years. Recurrence occurred in 12 cases. Primary varicose veins were bilateral in 76% of the cases. Long saphenous system was involved in all cases, while short saphenous was involved in 20% of the cases.

## DISCUSSION

Primary varicose veins is a disease of young adults

All correspondence to:  
Dr. Dilawar Mehmood Naeem  
Department of General Surgery, Combined Military Hospital,  
Lahore.

whose professional requirement forces them to stand for long hours. The concept of etiology is shifting towards primary venous wall defect and is attributed to defect in connective tissues. Incompetent valve is the manifestation of this defect which allows high pressure transmission to superficial veins. The cause of recurrence is usually inadequate initial operation with failure to perform flush ligation of saphenofemoral junction. Limited stripping of long saphenous veins upto upper calf in all cases should be done to avoid recurrence due to persisting mid thigh perforators. In the popliteal fossa sphenopopliteal junction should be carefully identified and ligated when there is short saphenous incompetence.

Surgery for primary varicose veins has quite low incidence of complications where patient selection is appropriate and surgical principles are followed.

#### REFERENCES

1. Barnabas A P, macfarlane R, 1985. The use of preoperative venography in the management of difficult primary and recurrent varicose veins. In : Greenhalgh RM (ed) Diagnostic techniques and assessment procedures in vascular surgery. Grune & Stratton, London, pp 447-458.
2. Campbell WB. Varicose veins. BMJ 1990;300:763-4.
3. Dodd, H., and F.B. Cockett: The pathology and surgery of the veins of the Lower Limb, Churchill Livingstone, Edinburgh, 1976.
4. Rivlin S. 1975. The surgical cure of primary varicose veins. Br. J. Surg 62: 913-917.
5. Elbaz C. Recurrence of varicose veins following surgery. J. Vasc Surg. 1989; 23:90-4.
6. Lofgren EP, Lofgren KA. Recurrence of varicose veins after the stripping operation. Arch Surg. 191; 102:111-14.

# LATE ONSET ESOPHAGEAL PERFORATION DUE TO GUNSHOT INJURY OF CHEST: SUCCESSFUL NONOPERATIVE MANAGEMENT IN A YOUNG CHILD.

## A Case Report

ASAD I. MIAN\*, SAIMA H. KHAN\*, M. NAEEM-UZ-ZAFAR KHAN\*\*

### ABSTRACT:

*Penetrating firearm injuries of the chest have become commonplace in children living in violent urban areas. Esophageal perforation may present as a late manifestation of paediatric thoracic trauma due to gunshot injury. Opinion varies as to the surgical or nonsurgical management of such a patient. The authors report a case of a 12-year-old girl who presented with a similar dilemma and her successful conservative management, that they opted for, is discussed.*

**KEYWORDS:** Esophageal perforation, firearm injuries, penetrating thoracic trauma.

### INTRODUCTION

Penetrating thoracic trauma by high-velocity projectile accounts for 10% to 15%<sup>1,2</sup> of childhood firearm injuries, and is on the rise.<sup>3,4</sup> It is the commonest cause of thoracic injury in children 12-years of age or older.<sup>5</sup> The lesions are diverse and may involve any intrathoracic structure.<sup>6</sup> Perforation of the esophagus, due to firearm, is the most severe complication of esophageal injury and a life-threatening condition that requires prompt diagnosis and treatment.<sup>3,7</sup> Unfortunately, damage to the esophagus due to intrathoracic trauma is often overlooked during the initial examination, or is not immediately apparent because of delay in presentation.<sup>8</sup> Management of cases of delayed onset esophageal perforation remains controversial.<sup>7,19</sup>

Herein we describe the case of a child who developed late onset esophageal perforation due to firearm injury of the chest. Her successful nonoperative management is reported and discussed as described in literature.

### CASE REPORT:

A twelve-year-old girl presented 24 hours after sus-

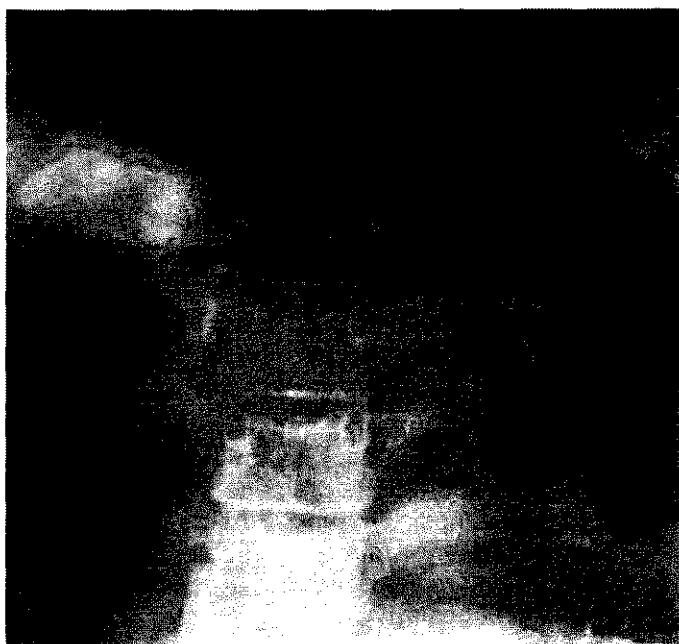taining a bullet injury of the chest. The injury had led to profuse bleeding from her right shoulder. The girl developed progressive difficulty in breathing and cyanosis. Bleeding was curtailed by pressure bandage until her arrival to the ER, where she was found to be in severe pain and obvious respiratory distress. She had heart rate of 120/min., respiratory rate of 30/min., and blood pressure of 90/60 mm of Hg. She had a 1cm. x 1cm. wound of entry along the posterior axillary fold on the left axilla, and the wound of exit was 5cm x 3cm along the right suprascapular region. Left side of the chest had decreased expansion and absent breath sounds. A chest radiograph showed an air-fluid level on the left and a needle thoracentesis was diagnostic for a hemopneumothorax. Immediate chest intubation was done and hemorrhagic fluid drained.

In the intensive care unit broad-spectrum intravenous antibiotics (a third generation cephalosporin, an aminoglycoside and metronidazole) were prescribed, and oral intake was allowed. The chest tube was removed after four days but subsequently the child developed a continuous high grade fever. Blood counts showed a persistent leucocytosis with neutrophilia. On the fifth day of admission, thick pus and saliva started oozing from the wound of exit, followed two days later by frank discharge of foul smelling food material from the same site. This was the first clinical indication of a delayed presentation of esophageal

All correspondence to:

M. Naeem-uz-Zafar Khan, Department of Paediatric Surgery, The Children's Hospital, P.I.M.S., Islamabad, Pakistan.

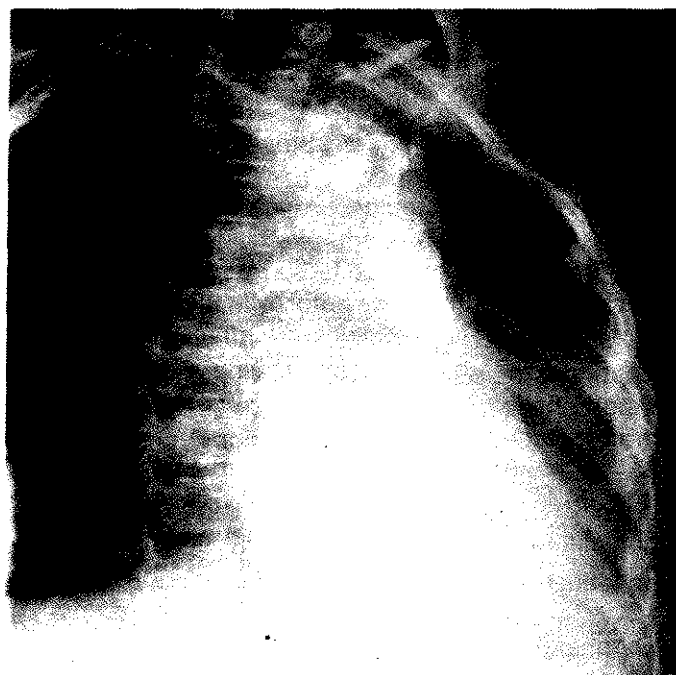
perforation, secondary to the transmediastinal trajectory of a projectile. A gastrografen (radiographic contrast) study under fluoroscopic control on the eighth post-traumatic day, confirmed the presence of a perforation of the thoracic esophagus at the level of the third thoracic vertebra. There was leakage of contrast that communicated with the skin through the wound of exit. Surprisingly, on the left side of the chest, leakage of contrast extends down to the level of the left dome of the diaphragm (Fig.1).



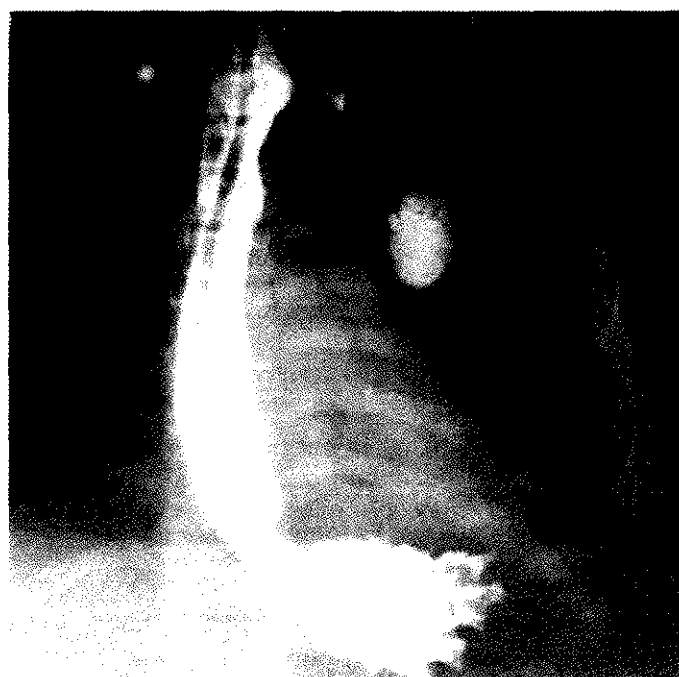**Figure 1.** Gastrografen contrast study performed eight days subsequent to thoracic gunshot injury confirmed esophageal perforation; leakage of contrast can be seen on both sides of the thorax (arrows).

The patient was put on nasogastric feeding in prop-up position, with a high caloric intake. Continuous suction at the wound of exit and toilet of the wound of entry was initiated, alongwith continuous pharyngeal suction and chest physiotherapy; intravenous antibiotic were continued. On the fourteenth post-trauma day, once again the left side of the chest showed diminished ventilation. A chest radiograph and a subsequent thoracentesis revealed a left-side empyema thorax, which was drained by a wide thoracostomy tube with an underwater seal. With the chest tube in place and continued drainage of the purulent fluid, and subsequent chest radiographs showed progressive improvement.

Conservative management of our patient helped put her on the path of steady recovery. Her Pyrexia settled and her thorax cleared. Chest tube was removed and subsequent chest radiograph showed clear lung fields. Repeat gastrografen contrast studies over subsequent weeks showed progressive reduction of the fistulous tracts (Fig. 2A & B).



**Figure 2A**



**Figure 2B.** Repeat gastrografen studies over the subsequent weeks showing progressive decrease in the sizes of the fistulous tracts. These were performed on the fifteenth (A) and the thirtieth (B) post-trauma days, respectively.

## DISCUSSION:

Whenever a penetrating wound to the chest has crossed the midline, one actively needs to exclude injury to the mediastinal structures, such as the heart, aortic arch, bronchial tree, and the esophagus, even though injury to such structures may not be immedi-

ately clinically apparent.<sup>8,9</sup> Esophageal perforations occur most commonly as an iatrogenic complication (75% to 77%),<sup>3,10,11</sup> with chest trauma accounting for only 2% to 10%<sup>1,3,10,12,13</sup> of all esophageal injuries. The esophagus is infrequently the site of isolated trauma because of its protected position and small diameter. The seriousness of perforation is heightened by the fact that the esophagus is surrounded by loose connective tissue that does not effectively prevent dissemination of infection and inflammation; without treatment the outcome usually is fatal.<sup>7</sup> However, most reports have been based on adult series with few children included. Thus the conclusions regarding etiology, treatment and outcome may differ and may not be directly applicable to the paediatric patient.<sup>7</sup> Few guidelines are available which facilitate treatment of patients with noniatrogenic injuries of the esophagus.<sup>14</sup>

Esophageal perforations due to penetrating trauma of the chest may lead to a linear tear in the esophagus allowing leakage into the mediastinum, producing mediastinitis, and immediate or delayed rupture into the pleural space, producing empyema.<sup>15</sup> These two complications were late manifestations in our patient. There are distinct clinical patterns of presentation, depending on the level of esophageal perforation. At least 75% of patients with perforation have dysphagia and excruciating pain on swallowing.<sup>15</sup> In the older child, severe pleuritic pain or substernal pain are the hallmarks of perforation. Fever may often be quite high and a rapid, toxic progression to shock may occur in patients of any age, but seems to be commoner in older children with free pleural involvement. However, esophageal perforations may occasionally present in an obscure fashion, as in our patient, without the dramatic explosion described above. In such instances, the diagnosis may be missed for many days or weeks.<sup>10</sup> Late sequelae are rare because patients do not survive the initial trauma or because the injury is recognized early and treated appropriately.<sup>16</sup> In our patient a fistula between the esophagus and skin via the wound of exit was a late sequela because of unrecognized trauma to the esophagus.

Early diagnosis of esophageal perforation is suspected clinically and confirmed radiologically.<sup>15</sup> The results of plain radiographs of the chest and neck will suggest the diagnosis in the majority of cases.<sup>7</sup> Characteristic findings are subcutaneous emphysema, pneumomediastinum, pleural effusion and/or pneumothorax, which were absent in our patient. It is noteworthy that upper thoracic perforations, as in our case, present with left-sided effusion, while lower thoracic perforations have

right-sided signs. This is contrary to previous findings.<sup>7</sup> Anatomically the left pleura is closely related to the esophagus in the superior mediastinum, whereas the right pleura is in intimate contact with the distal two-thirds of the esophagus, except where it is crossed by the azygos vein. This most likely accounts for the pattern of presentation. Plain radiographs should be followed by water-soluble (e.g. gastrograffin; diatrizoate meglumine) study to accurately delineate the pathology. If contrast study findings are negative in a case of suspected perforation, a dilute barium study should be performed.<sup>11,17</sup> Esophagoscopy offers no diagnostic advantages and may in fact enlarge the perforation, complicating subsequent repair.<sup>15</sup>

The most appropriate therapy for esophageal perforation depends on the site of perforation, the interval between the perforation and its recognition, and the systemic response to injury.<sup>10</sup> In the past authors discouraged conservative (i.e. nonoperative) management that was proposed by Mengoly and Klassen in 1965.<sup>10</sup> The "drain and hope" regimen was thought to be a disappointment and hence a more aggressive approach was advocated. They suggested that primary suture with appropriate drainage should be attempted in early diagnosis (within 24 hours of perforation); for late cases only drainage should be performed. However in recent years varying accounts of management and prognosis have been reported for late recognized perforation. Some current studies reveal that despite a high incidence of associated complications, survival following esophageal perforations is high and the impact of delayed diagnosis is decreasing.<sup>12,14</sup> On the other hand, others still report high morbidity and mortality due to delayed diagnosis and continue to advocate a surgical approach.<sup>18</sup>

Literature review revealed controversial management options for cases in which the delay in diagnosis exceeds 24 hours.<sup>7,19</sup> In our patient, the perforation was a delayed manifestation of firearm injury. We opted for a conservative approach. Our management is in contrast to protocols for adults, for whom the gold standard remains early aggressive surgical therapy, aiming for primary closure of the defect.<sup>7,19,21</sup> We conclude that with appropriate conservative management, a good outcome can be expected with a traumatic esophageal perforation presenting late.

## REFERENCES:

1. Nance, M.L. Sing R.F., Reilly P.M., et al: Thoracic gunshot wounds in children under 17 years of age. *J Pediatr Surg.* 1996, 31(7):931-35.

2. Nance M.L., Templeton J.M., O'Neill J.A.: Socioeconomic impact of gunshot wounds in an urban pediatric population. *J Pediatr Surg.* 1994, 29:39-43.
3. Postlethwait R.W.: *Surgery of the esophagus.* New York, Appleton-Century-Crofts, 1979.
4. Zavoski R.W., Lapidus G.D., et al: A population-based study of severe firearm injury among children and youth. *Pediatrics.* 1995, 96(2 Pt 1):278-82.
5. Meller J.L., Little A.G., Shermata D.W.: Thoracic trauma in children. *Pediatrics.* 1984, 74:813.
6. Reinberg O., Genton N., Lacheretz M.: Particularities of thoracic trauma in children. In: Webb W.R., Besson A. (eds.): *Thoracic surgery: Surgical management of chest injuries* (chapter 34). St. Louis, Mosby-Year Book, 1991, 7:340.
7. Panieri E., Millar A.J.W., et al: Iatrogenic esophageal perforations in children: Patterns of injury, presentation, management, and outcome. *J Pediatr Surg.* 1996, 31(7):890-95.
8. Haller J.A. Thoracic injuries. In: Welch K.J., Randolph J.G., Ravitch M.M., et al: *Pediatric surgery.* Chicago, Year Book Medical Publishers, Inc. (chap 17); 1986, 143-53.
9. Falcon O., Knott C., Elkins R.C. Gunshot wounds traversing the mediastinum: Guidelines for evaluation and management. *J Okla State Med Assoc.* 87(4): 1994, 174-7.
10. Popovici, Z.: Esophageal injuries. In: Webb, W.R.; Besson, A. (eds.): *Thoracic surgery: Surgical management of chest injuries* (chap 45). St. Louis, Mosby-Year Book. 1991, 7:443-66.
11. Sawyer R., Phillips C., Vakil N. Short and long-term outcome of esophageal perforations. *Gastrointest endosc.* 1995, 41(2):130-4.
12. Reefder L.B., DeFilippi V.J., Ferguson M.K.: Current results of therapy for esophageal perforations. *Am J Surg.* 1996, 169(6):615-7.
13. Besson A., Savary M.: Trauma of the esophagus. In: Besson A., Saegesser R. (eds.): *SA colour atlas of chest trauma and associated injuries* (chap. 11) London, Wolfe Medical Publications, Ltd. (2): 1983, 251-316.
14. Weimam D.S., Walker W.A., Brosnan K.M.: Noniatrogenic esophageal trauma. *Ann Thorac Surg.* 1995, 59(4):845-9.
15. Weber T.R.: Esophageal rupture and perforation. In: Welch K.J., Randolph J.G., Ravitch M.M.; et al: *Pediatric Surgery* (chap 73) Chicago, Year Book Medical Publishers, Inc.: 1986, 725-27.
16. Deslauriers J., Desaulniers D., Pomerleau S.: Late sequelae of thoracic injury. In: Webb W.R., Besson A. (eds.): *Thoracic surgery: Surgical management of chest injuries* (chap. 48) St. Louis, Mosby-Year Book, Inc.; vol 7: 1991, 513-35.
17. James A.E., Montaly R.J., Chafee V., et al: Barium or gastrografin: which contrast media for diagnosis of esophageal tears? *Gastroenterology*, 1975, 68:1103.
18. Andrade A.R. T-tube intubation in the management of late traumatic esophageal perforations: Case report. *J Trauma.* 1994, 37(1):131-2.
19. White R.K., Morris D.M. Diagnosis and management of esophageal perforations. *Am Surg.* 1992, 8:112-19.
20. Santos G.H., Frater R.W.M. Transesophageal irrigation for the treatment of mediastinitis produced by esophageal rupture. *J Thorac Cardiovasc Surg.* 1986, 91:57-62.
21. Flynn A.E., Verrier E.D., Way L.W., et al: Esophageal perforations. *Arch Surg.* 1989, 124:1211-14.

RECEIVED  
JAN 10 1997  
JOURNAL OF SURGERY  
PAKISTAN (INTERNATIONAL)  
VOL. 2 (1)

# PHYTOBEZOAR OF SMALL INTESTINE

## A Case Report

ABDUL SATTAR MEMON, JAN MOHAMMAD MEMON, ABDUL GHANI SOOMRO

### ABSTRACT

*Phytobezoar of small intestine in middle age group is rare. We report one such case in a 50 years old female patient suffering from abdominal tuberculosis with phytobezoar. Following antituberculous treatment and surgery, patient recovered completely.*

**KEY WORDS:** Small intestine : Phytobezoar

### INTRODUCTION

Bezoar is derived from Arabic word "BEDZEHR" meaning antidote. Debakey and Ochsner<sup>1</sup> has classified bezoar into 3 categories.

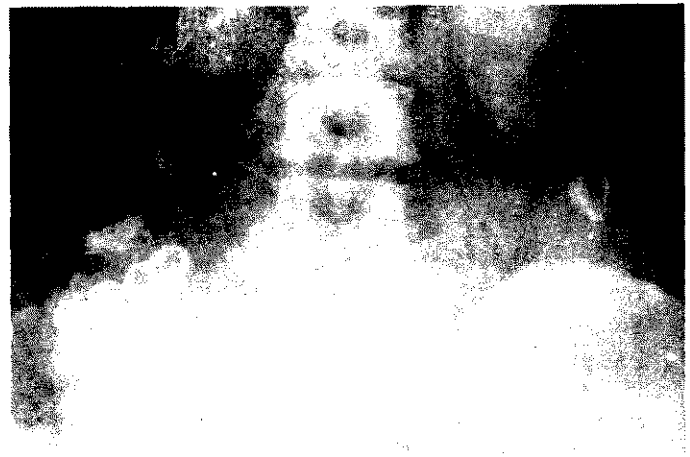
1. Trichobezoar or hair ball composed of masses of hair and decaying food materials.
2. Phytobezoar consists of entangled masses of vegetable, fibrous material, such as skin, seeds, vegetable and fruit fibers.
3. Hard concretions which consist of organic masses or calculi containing calcium.

### CASE REPORT


A fifty years old widow was hospitalized with colicky abdominal pain, vomiting and distension of abdomen. She gave history of such attacks in the past. Abdominal examination revealed palpable stones in right lower abdomen, which were mobile, bowel sounds were exaggerated. X-ray abdomen revealed multiple radio-opaque shadows in the abdomen (Fig. 1). Ultrasound was normal. Her hemoglobin was 8.0gm% and ESR102mm in first hour.

With the diagnosis of subacute intestinal obstruction, laparotomy was performed. Two strictures 25 cm. apart were seen in the terminal ileum 30 cm. from ileocaecal junction. Intestinal loop between the two strictures contained phytobezoar (seeds of various fruits and vegetables). Resection of the loop containing phytobezoar (Fig.2) was done followed by end to end anastomosis of ileum. A mesenteric lymph node was taken for biopsy; which revealed tuberculous granuloma. Patient was prescribed anti-tuberculous drugs for six months. At seven months followup patient is in good health.

All correspondence to:  
Dr. Abdul Sattar Memon, Department of Surgery, Liaquat Medical College, Jamshoro, Sindh, Pakistan.



**Figure 1** X-Ray abdomen revealing Radio opaque phytobezoar in small intestine.



**Figure 2** Phytobezoars (various seeds) removed from terminal ilium.

## DISCUSSION

Bezoars are commonly seen in young ladies with psychiatric disorders. Bezoars after gastric surgery are reported quite frequently because of reduction of acid and pepsin and also disturbance of antral function. Citrus fruits with large amounts of cellulose are also a common cause. Recently many iatrogenic bezoars secondary to medications have been reported<sup>2</sup>. Formation of intestinal bezoars after gastric surgery may be due to delayed emptying. First such case after vagotomy was reported by Oliver<sup>3</sup>.

It is possible to dissolve phytobezoar by papain (Proteolytic enzyme) if administered with sodium bicarbonate, as later is mucolytic and also facilitates the action of papain. Combination of enzymes e.g. cellulose and dehydroxycholic acid are also effective. Conservative

treatment, however, is effective in small percentage of patients only. Surgery is required in cases where conservative treatment fails.

## REFERENCES

1. Debaeky M., Ochsner A. Bezoars and concretion, Comprehensive review of literature with analysis of 303 collected cases and presentation of 8 additional cases. *Surgery* 1983, 4:934-63.
2. Forrucci JR, Eaton AB. Complications of drug therapy. In Margnilus AR, Burnhew HJ (eds.) *Alimentary tract roentgenology*, 2nd ed. St. Louis C. Y. Mosby Co. 1973, 281-93.
3. Oliver, Prevest 1966 *Prease Medical* 74-387.

## SURGICAL PROGRAMME FOR 1997

January /Feb	Launching of Journal of Surgery Pakistan
February	J.P.M.C. Symposium
March	Congress 97 at Dhaka - Joint Conference of Bangladesh College of Physicians & Surgeons with CPSP
April	Symposium on 'Training of Surgeons - structured programme' by ICS
May	Symposium on Disaster Plan for the city of Karachi by ICS
June	Asia Pacific Conference of ICS in Singapore
July	Guest Lecture by Prof. Earnest Owen, President International College of Surgeons
August	Hands on workshop on Animal Transplantation by ICS
September	Symposium on ' Undergraduate Training Programme by ICS
October	Symposium on 'Surgical Problems in the SARRAC country' by ICS
November	Symposium on Oncology - 'Lung Malignancies' by ICS
December	Workshop on 'Vascular Surgery' by ICS



# CONGENITAL LOBAR EMPHYSEMA

## A Case Report

JAMSHED AKHTAR, ZAKAULLAH WAQASI, ABDUL AZIZ

### ABSTRACT

*Congenital cystic lesions of lungs are rare. We report a case of congenital lobar emphysema in a six week old male baby who presented with respiratory distress and cyanosis. Following resuscitation and improvement in general condition, patient was operated upon. Middle lobe of right lung was massively distended and was removed. Postoperative recovery was uneventful. At three months follow-up patient is thriving well.*

**KEY WORDS:** Congenital cystic lung disease, Congenital lobar emphysema, Pulmonary lobectomy.

### INTRODUCTION

Congenital cystic disease of lung includes four classic lesions: that present as abnormal cystic areas within hemithorax and include congenital cystic adenomatoid malformation, bronchogenic cyst, pulmonary sequestration and congenital lobar emphysema<sup>1</sup>. Although histologically they are different from each other but they usually have similar clinical presentation and are often difficult to diagnose and always require surgery<sup>2</sup>. We report our experience of one such lesion.

### CASE REPORT

A six weeks old male baby weighing 3.4 kg presented with respiratory distress and cyanosis. Birth history was unremarkable. At the age of two weeks patient developed fever and became increasingly dyspnoeic. He was initially put on intravenous antibiotics and respiratory support with very little improvement before transfer to NICH. X-rays and C.T. scan of chest revealed space occupying cystic lesion in the middle zone of right lung with compression of upper and lower lobes on the same side and shift of mediastinum to the opposite side. (Fig 1).

Following resuscitation and improvement in general condition patient was operated upon through right lateral thoracotomy. On opening the chest, middle lobe herniated through the incision. It was pale pink, spongy and did not deflate on compression. Upper and lower lobes were collapsed. Right middle lobe lobectomy was performed following which the remaining lung expanded. Chest tube was placed and connected to an under water seal. Postoperative recovery was uneventful with full expansion of lung. (Fig 2). At three months follow-up patient is thriving well.




Figure 1 C.T. Scan of chest showing cystic lesion of right lung.

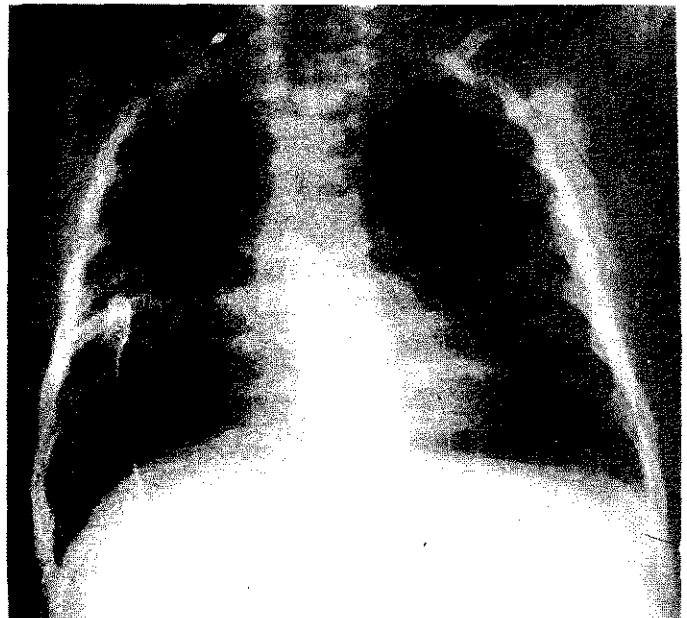


Figure 2 X ray chest showing expansion of right lung following surgery

All correspondence to:  
Jamshed Akhtar, Department of Paediatric Surgery, National Institute of Child Health, Karachi, Pakistan.

## DISCUSSION

Congenital lobar emphysema is a rare lesion of lung in which massive overinflation of one of the lobes of lung occurs. The involved lobe cannot deflate because of intrinsic or extrinsic obstruction of its lumen. Most commonly left upper lobe is involved followed by right middle lobe. Lower lobes are rarely involved<sup>3</sup>. Usually the patient presents in emergency with severe respiratory distress and cyanosis. Chest radiograph is characteristic in which lung markings can be seen in overinflated lobe which differentiates this condition from tension pneumothorax. Bronchoscopy is indicated only if facilities for emergency surgery are at hand as it can exacerbate air-trapping. Non-operative treatment carries high mortality. Patients who had lobectomy in neonatal period in a series reported by McBride and Colleagues had normal or near normal lung volumes, suggesting that compensatory growth can occur<sup>4</sup>. The potential for life threatening complications

stresses the importance of early lobectomy in this malformation which is very well tolerated even in neonatal period with excellent long term prognosis.

## REFERENCES

1. dell' Agnola CA., Tadini B, Mosca F, Wesley JR. Prenatal ultrasonography and early surgery for congenital cystic disease of the lung. *J Pediatr Surg* 1992; 27: 1414-7.
2. Buntain WL, Issacs H, Payne VC, et al. Lobar emphysema, cystic adenomatoid malformation, pulmonary sequestration and bronchogenic cyst in infancy and childhood. A clinical group. *J Pediatr Surg* 1974; 9: 85-93.
3. Keith H.H. Congenital lobar emphysema, *Pediatr Ann* 1977; 6: 36-41
4. McBride JT, Wohl ME, Strieder DJ, et al. Lung growth and airway function after lobectomy in infancy for congenital lobar emphysema. *J Clin Invest* 1980; 66: 962-70.

## INTERNATIONAL SURGICAL CONGRESS 97

International Surgical Congress 97 was held on 3rd and 4th January 1997 in CPSP premises with the collaboration of International College of Surgeons (Pakistan Chapter), SAARC Association of Surgeons, (Pakistan Chapter) and Society of Surgeons (Centre and Karachi Chapter). The election of Society of Surgeons Centre was held on 3rd January 1997 and was followed by a dinner in the evening. The Congress was inaugurated by the Sind Governor, Mr. Kamaluddin Azfar on 4th January 1997 and was followed by the scientific session.

Delegates from Lahore, Islamabad, Multan and Quetta attended the Congress. Prof. F.U.Baqai, Chairman and Dr. Asadullah Khan, Secretary of the Congress thank all participants for making the Congress a success.

# BILATERAL RENAL AGENESIS IN A PARASITIC TWIN WITH FEATURES OF POTTER'S SYNDROME:

## A Case Report and Review of Literature

AMANA NASIR\*, FAIZAH N. BHATTI\*, FARAH KHAN\*, AMJAD CHAUDHRY\*\*,  
M. NAEEM UZ ZAFAR KHAN\*\*

### ABSTRACT

*It is known that in cases of parasitic conjoined twins, one of the twins may have bilateral renal agenesis (BRA); however, it is rare to have all the features of Potter's syndrome. In this case report we noted most of the features and the associated abnormalities that occur with this syndrome in an omphalopagus type of parasitic twin. The other twin (autosite) was completely normal in organogenesis and function, and was responsible for sustaining the parasite's circulation.*

**KEY WORDS:** *Potter's syndrome , parasitic twinning, Bilateral renal agenesis*

### INTRODUCTION

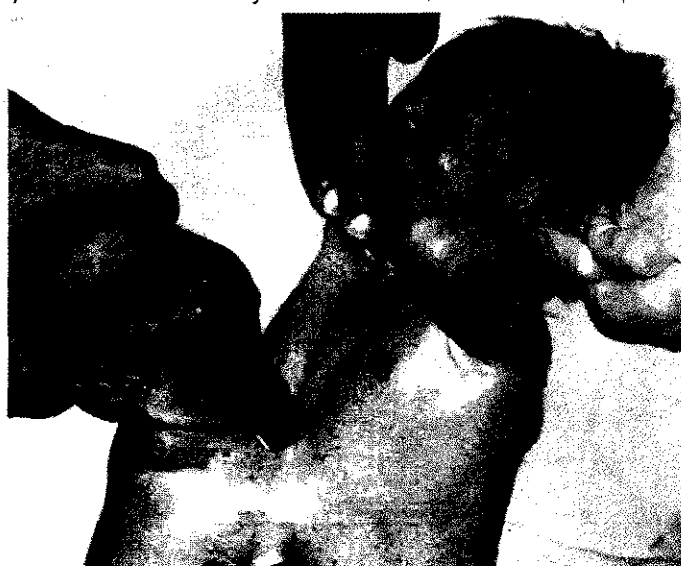BRA is incompatible with life. Immediate mortality is because of associated pulmonary insufficiency rather than from renal failure. A considerable number are stillborn. The interesting features associated with this condition are several, namely pulmonary, gastrointestinal, lower urinary tract and skeletal abnormalities, that seem to follow a definite pattern. Potter described one such set of abnormalities. Although most cases are incompatible with life, but they provide us with knowledge of embryological events and during pregnancy, the importance of monitoring specific features with ultrasound, for example oligohydramnios. Early termination of pregnancy is indicated in a single fetus, but in case of conjoined twins often one baby with no abnormalities may be saved.

### CASE REPORTS:

A set of sixteen hours old conjoined twins were born to parents of consanguineous marriage. Previously the parents had five children, three girls and two boys. The first three had died at seventh, tenth and twelfth days respectively after birth. No definite cause of death could be elicited. The last two children, a boy of five and a girl of three have survived. There was no history of maternal illness.

No pregnancy was monitored and all the deliveries had taken place at home.

On examination conjoined twinning was omphalopagus parasiticus type (Fig: 1 and Fig: 2). The autosite was complete, both externally and internally. The parasite, who was sustained by the autosite, had a number of dysmorphic features namely low set ears, bilateral cleft lip and



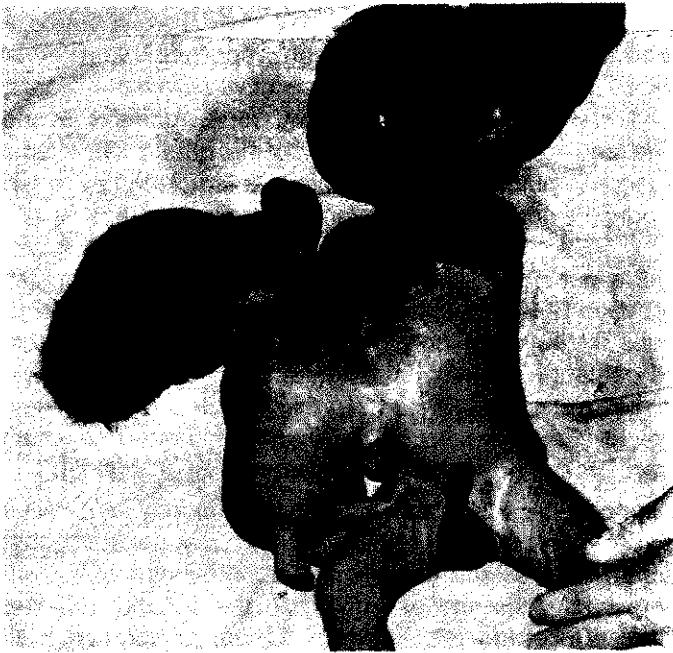**Figure 1** Most facial features of Potter's syndrome are present in parasitic twins namely, hypertelorism, micro-ophthalmia, epicanthic folds, hare nose, position deformity of ears and hypoplastic limbs.

\*Aga Khan University Medical College, Karachi, Pakistan

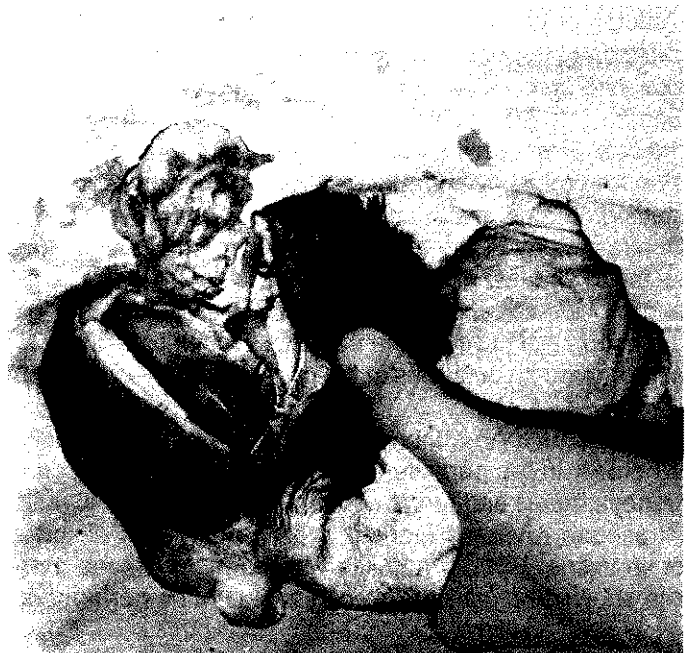\*\*Department of Paediatric Surgery, Children Hospital, Pakistan Institute of Medical Sciences, Islamabad, Pakistan.

All correspondence to:

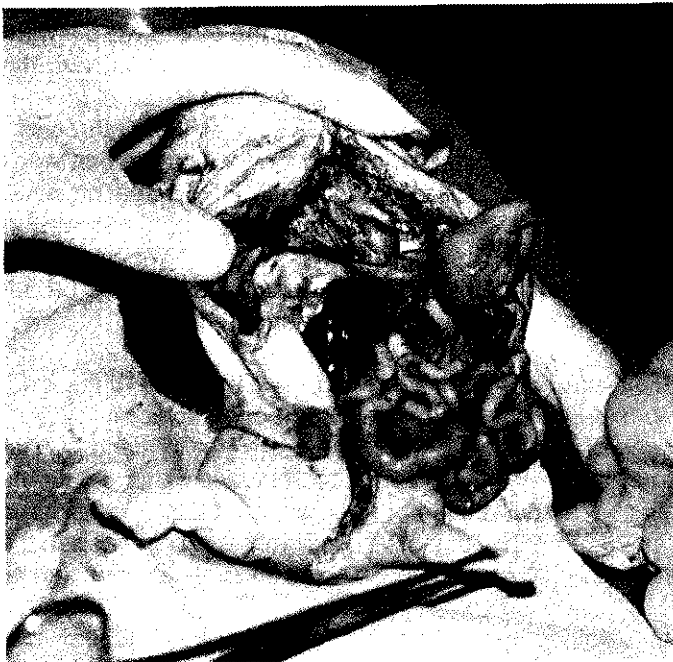
Prof. M. Naeem-uz-Zafar Khan, Department of Paediatric Surgery, Children Hospital, Pakistan Institute of Medical Sciences, Islamabad, Pakistan.



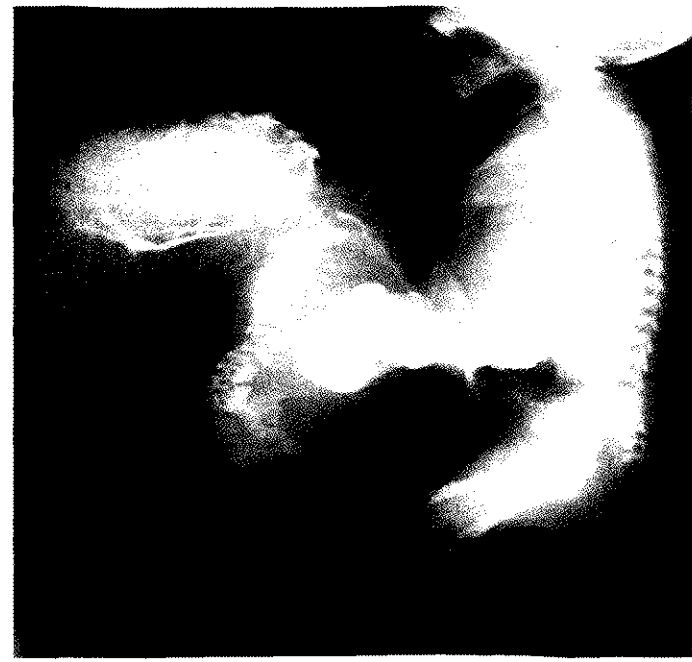**Figure 2** Hydrocephaly, encephalocele and tibiofibular deficiency in right, and femoral deficiency on the left lower hypoplastic limbs.



**Figure 4** Hydrocephaly with encephalocele, large amount of C.S.F. is being drained and compressed hypoplastic brain is brought out.



**Figure 3** Viscera of parasite with hypoplastic lungs and heart, oesophagus and intestinal atresia. Absent kidney and urinary bladder with Bockdalek hernia.



**Figure 5** Skeleton of parasite demonstrates deficiency of bones in hypoplastic limbs and defects in skull due to encephaloceles, gastrointestinal contrast study shows intestine of autosite overlapping into parasite's abdominal cavity.

palate, microphthalmia, excessively flattened nose with hypertelorism (Fig:2 ). There were limb deformities with vestigial right upper limb bud, the left arm was large and had radial clubbing. The lower limbs were hypoplastic with proximal femoral deficiency on one and vestigial tibia and fibula on the other lower limb (Fig:2). The penis was vestigial and the patient had high anorectal agenesis. There was no demonstrable motor or sensory activity in the par-

asite. There were only conducted movements with the movements of autosite.

On investigations skeletal survey revealed normal skeleton of the autosite except for the sternum which was fused with the sternum of the parasite. The parasite had 9 pairs of visible ribs, a complete but abnormal vertebral column with pelvis and complete sacral agenesis. Both scapulae were

vestigial. One limb had complete lower radius and ulna and skeleton of the hand had four metacarpals and digits. The skeleton of the thumb was absent with radial clubbing. The skull had an occipital defect from where the encephalocele was bulging (Fig:4). There were hypoplastic mandible and maxilla. Esophagus could not be cannulated and because of anorectal agenesis, gastrointestinal tract could not be studied. Lungs were not visible (being not ventilated). Contrast study of the autosite showed normal esophagus, stomach and rest of the intestine, much of the small bowel had prolapsed through the omphalopagus connection into the abdominal cavity of the parasite. The autosite and parasite shared an umbilicus at the base of their fusion. (Fig:5)

On ultrasound no abnormality was noted in the autosite. Whereas, in the parasite there were hypoplastic liver and kidneys; heart and lungs could not be visualized. Cranial ultrasound revealed marked hydrocephaly with distorted brain tissue. EEG of autosite was normal whereas parasite showed no activity. CT scan could not be performed.

At operation, besides the general physical findings already described, the fusion was along the umbilicus upto the xiphisternum, where the sternum of the autosite had fused with sternum of the parasite. There was a large arterial and venous connection arising from the autosite adjacent to the liver which was perfusing the parasite. The parasite had loops of small intestine and vestigial colon which ended blindly in what appeared to be prostatic tissue in the pelvis. The penis was vestigial and testis and scrotum were absent. There was no organised bladder, ureter or kidney. Liver was fairly well formed with a fibrous connection with the liver of the autosite. There was a vestigial gall bladder, a small spleen and a Meckel's diverticulum. Some loops of intestine and spleen of parasite had prolapsed through a posterolateral defect in the left diaphragm (Bochdalek hernia). The lungs were like buds with poorly formed tracheobronchial tree and there was a hypoplastic heart within the pericardial cavity (Fig:3) and poorly developed aortic and pulmonary vessels. The face had the appearance of premature senility which is sufficiently characteristic to warrant a diagnosis of co-existing renal aplasia.

This detailed scrutiny of the parasite revealed that most features were similar to abnormalities found in Potter's syndrome.

## DISCUSSION

Degrees of defective renal development range from complete failure of formation of the kidneys to occurrence of varying quantity of renal tissue. Renal agenesis is a condition in which no nephrogenic tissue is present, and is reported to occur in 1 in 4000 births, with a male predominance of 3 to 1<sup>1</sup>. Excluding parasite and formless mon-

sters, the earliest report of bilateral renal agenesis [BRA] was in 1671<sup>6</sup>. Although most cases of BRA are sporadic, a familial pattern has also been reported. Cain et al described a family with two consecutive born male infants, the first with BRA and the other with renal agenesis on one side and total renal dysplasia on the other<sup>1</sup>. With renal agenesis, pulmonary hypoplasia is a feature and this will produce signs of respiratory insufficiency.

There does not seem to be any significant relationship between BRA and maternal age or parity. In some set of twins like our case, only one of the pair has been affected. 66 percent or more of these infants are reported as premature but it is suggested that this reflects a failure to gain weight after 34 weeks, rather than a shortened gestation time. Breech presentation of infant with BRA is usual. The diagnosis is usually confirmed only at autopsy<sup>6</sup>. A detailed autopsy is vital in assessment of an infant with oligohydramnios to establish congenital abnormalities of the urinary tract. This applies equally to the second trimester fetuses following miscarriages, therapeutic abortion, still-born infants and cases of neonatal deaths<sup>10</sup>.

Of all the children born with bilateral renal agenesis about 33 percent will be stillborn, most of the others will die within 24 hours. A rare 6 percent of patients who survive the respiratory insufficiency live long enough to die of uremia. The longest survival has been 39 days. The first three siblings of our conjoined twins had died within the first week of birth. About 25% of infants with BRA have no other anomalies. Various associations have been reported in these children. The interrelationship is not yet clear but it is possible that all are different manifestations of a broader axial mesodermal "dysplasia" syndrome.

BRA may be detected prenatally by fetal ultrasound. Normal kidneys can be detected sonographically by 20th week of gestation. If the kidneys are not in place by that time, failure to demonstrate the bladder within 1-2 hours after I/V administration of lasix to the mother is considered confirmatory. The diagnostic criteria for renal agenesis in the early fetus differs from those in the second half of gestation.

In conjoined twins where the aim is to save both individuals a detailed study of organogenesis and function in both is required before surgery. But in a case of parasitic twinning like in our case there is no difficulty to arrive at a decision, as only the autosite has to be saved.

## REFERENCES

1. CHESTER M. EDELMANN Jr. Renal Abnormalities And Malformation Syndromes. Paediatric Kidney Disease. Second Edition Little, Brown and Co [Inc]. 1992.
2. BEHRMAN AND VAUGHAN. Kidney Problems In

- Newborn Infants. Nelson Textbook Of Paediatrics. Fourteenth Edition. W.B. Saunders and Co. 1992.
3. RICHARD S.SNELL The Genitourinary System. Clinical Embryology. Third Edition. Little, Brown and Co [Inc]. 1983
  4. ELLIN LIBERMAN Congenital Malformation of Urinary Tract With or Without Infection. Clinical Paediatric Nephrology. J.B. Lippincott and Co. 1976.
  5. KEITH L. MOORE The Genitourinary Tract. The Developing Human. Third Edition.
  6. SKANDALAKIS AND GRAY Embryology For Surgeon. Second Edition Abnormalities Of The Amount Of Renal Tissue.
  7. MARC I. ROWE Essential Of Paediatric Surgery. Renal Disorders.
  8. LOWE P. DEHNER Paediatric Surgical Pathology. Second Edition. Congenital And Developmental Anomalies.
  9. BRONSTEIN M.; AMITT A. Prenatal diagnosis. April 1994. The Early Prenatal Sonographic Diagnosis of Renal Agenesis: Techniques and possible pitfalls.
  10. British Journal (Obs. & Gynae.) July 1994 Title: Oligohydromnios sequence; The Spectrum of Renal Malformation.

# ACUTE INTERMITTENT PORPHYRIA SIMULATING ACUTE SURGICAL ABDOMEN

## A Case Report

FAISAL AHMED, JAMAL ARA, RUKHSANA SATTAR, SHABEER HUSSAIN.

### ABSTRACT

*A case of porphyria, an autosomal dominant, metabolic disorder, running in a whole family, is reported. The patient is the only survivor of a family; who presented as an Acute Abdomen.*

**KEY WORDS:** Rare Metabolic Disorder, Severe Abdominal Pain, Inherited disease, Proper Diagnosis, Porphyria, Acute Intermittent Porphyria.

### INTRODUCTION

Porphyrias are a relatively uncommon group of metabolic disorders, usually inherited<sup>1,2</sup>, in which there are abnormalities at various levels of Haem biosynthetic pathway<sup>3,4</sup>. Depending on the type of porphyria, excess production and concomitant accumulation of the intermediate products called porphyrins occur<sup>5</sup>. The Most important part in the management is family screaming to prevent other members from acute attacks<sup>6,8</sup>. A case report of Acute Intermittent Porphyria presenting as acute abdomen is presented<sup>7</sup>.

### CASE REPORT

A 14 years old school boy presented in the casualty department of JPMC, with the complaints of abdominal pain, constipation and disordered orientation for 5 days and fever for 8 days. About 7 hours prior to admission, he also developed urinary retention.

The patients was alright 8 days ago when he developed fever, for which he was treated by a local doctor. Three days later he developed abdominal pain which prevailed throughout but fluctuated in severity and responded to certain injections prescribed by the local doctor. He was constipated which became absolute a few hours prior to admission. Alongwith these com-

plaints the patient developed disordered orientation; spectrum of which fluctuated between anxiety and frank psychotic behavior. He gave no history of skin blistering or photosensitivity. Two of his sisters had died at the ages of 13 and 14 respectively, of disease with similar signs and symptoms. His father had died at the age of 28 of a disease whose nature could not be ascertained. There is a history of consanguinity in the family dating back to the last three generations.

The patient had visited the hospital on four different occasions, but was either discharged because he was found to have no surgical pathology, or referred to neuropsychiatric department, in view of his obvious behavioral disorder.

Clinical examination showed that he had a very rapid pulse and a blood pressure of 150/100mm of Hg. He was disoriented and paranoid complaining of excruciating abdominal pain; but there was no abdominal tenderness. His deep tendon reflexes were normal. he was catheterized because of urinary retention, and on examination of the urinary bag a short while later, the urine had turned darker in the urine bag, Ehlrich's test was performed and was affirmative. Other investigations showed reactive neutrophilia, Na<sup>+</sup> concentration 120 meq/L and urea 43mg/L. A diagnosis of Acute Intermittent Porphyria was thus confirmed.

### DISCUSSION

As the mortality of an acute attack of this disease is

Dr. Faisal Ahmed.

Department of Medicine,  
Jinnah Postgraduate Medical Center  
Karachi.

very high, and keeping in view its relative, though anecdotal, low incidence in our setup, and also considering the fact that this is an autosomal dominant disease<sup>9</sup>, which should have a relatively equal incidence in various communities. Patients are often shuffled between surgical and psychiatric Departments because of various behaviour changes in this illness<sup>1,9</sup>. It is tentatively concluded that this condition is not diagnosed correctly, a number of times, to facilitate prompt and life saving treatment. Therefore, in all cases of acute severe abdominal pain, not within the surgical parameters, metabolic disorders like porphyrias should be kept in mind.

## REFERENCES

1. Patience DH, Blackwood DH, McColl-KG, Moore MR, Acute Intermittent Porphyria and Mental Illness - A Family Study *Acta-Psychiatr-Scand* 1994 Apr; 89(4) : 262-7.
2. Sagene Laegreid, A etal Genetic Carrier Detection in Norwegian Families with acute intermittent Porphyria, *Scand -J-Clin-Lab-Invest*. 1993 Nov, 53(7): 687-91.
3. Mgone-CS; Lanyon-WG; Moor-MR; Louie-GV; Connor-JM, Identification of five novel mutations in the porphobilinogen deaminase, *Hum-Mol-Genet*. 1994 May; 3(5) : 809-11
4. Lundin-G; Wedell-A; Thunel-S; Anvert-M, Two new mutations in the porphobilinogen deaminase and a screening method using PCR amplification of specific alleles. 1994 Jan; 93(1) : Anvert-M. *Hum-Genetics*.
5. Hernandez-A; Sepulveda-P; Fernandez-Cuartero-B, De-Salamanca-RE. Urinary porphyrinogens in normal subjects and in patients with porphyria cutanea tarda and acute intermittent porphyria. *Horm-Metab-Res*. 1993 Aug; 25(8) : 454-4.
6. Abid-S; Jafri-SW; Abbas-Z; Khan-AH; Khan-MA. Acute intermittent porphyria—a diagnosis to consider. *JPMA-J-Pak-Med-Assoc*. 1995 Feb; 45(2) : 45
7. Shively-BD; Clochesy-JM; Briones-JP; Spositio-DL; Kloos-JA. Caring for patients with acute intermittent porphyria. *AACN-Clin-Issues*. 1994 Feb; 5(1) : 36-41
8. el-Shazly-M. Acute intermittent porphyria: a family study. *Br-J-Hosp-Med*. 1995 Feb; 53(4) : 169-70
9. Santosh-PJ; Malhotra-S. Varied psychiatric manifestation of acute intermittent porphyria. *Biol-Psychiatry*. 1994 Dec 1; 36(11) : 744-7
10. Whatley-SD; Roberts-AG; Elder-GH. De-novo mutation and sporadic presentation of acute intermittent porphyria. *Lancet*. 1995 Oct 14; 346(8981) : 1007-8.