

# Ovarian Ectopic Pregnancy: A Rare Condition

Ambreen Amna Siddiqui, Farkhunda Nadeem, Pushpa Sirichand

## ABSTRACT

*Pregnancy of extra-uterine origin can be a serious condition that demands early diagnosis and prompt treatment to save life of the women. Apart from tubal ectopic, ovarian ectopic pregnancy is the second common but rare type of extra-uterine pregnancy. A patient who has been using long term injectable contraception presented with 8 weeks amenorrhea followed by irregular bleeding per vaginum. Spiegelberg criteria were fulfilled. Laparotomy and histopathology confirmed ovarian ectopic pregnancy.*

*Key words* Ovarian ectopic pregnancy, Injectable contraception, Transvaginal ultrasound scan.

## INTRODUCTION:

Ovarian ectopic pregnancy is difficult to diagnose because of its rare occurrence. It is found in about 0.15%-3% cases.<sup>1-3</sup> It has different clinical presentations that varies from lower abdominal pain, vaginal spotting to menstrual irregularities etc.<sup>1</sup> Clinical examination as well as transvaginal ultrasound is helpful in making the diagnosis.<sup>4</sup> Herein we present one such case.

## CASE REPORT:

A 23 year old Gravida 4, Para 3 was admitted with complaints of lower abdominal pain and heavy frequent vaginal bleeding following amenorrhea of eight weeks. She has visited many consultants and received multiple courses of antibiotics but her symptoms never improved. She was married for 11 years. Her previous menstrual cycles had been normal. She had three spontaneous vertex deliveries at home, the last born was three and a half year of age. Since the last delivery she has been using long acting progesterone for contraception. Last injection was given three months ago. Her previous menstrual cycles had been normal except for heavy flow for the last 3 months.

On physical examination the abdomen was soft non tender. On speculum examination there was slight bloody discharge from the cervix. On digital vaginal examination the cervix was firm and os was closed. The uterus was of normal in size and mobile.

## Correspondence:

Dr. Ambreen Amna Siddiqui  
Department of Obstetrics & Gynecology  
Isra University Hospital, Hala Road,  
Hyderabad Sindh  
E mail: ambreendoctor@gmail.com

About 4-cm non tender mass was palpable in the left adnexal region. Her routine hematological and biochemical tests were within normal limits. Serum beta hCG was 582 IU/ml. Transvaginal ultrasound scan revealed a left adnexal hyperechogenic mass measuring 34 cm x 38 cm. The endometrium was 9 mm thick and there was moderate free fluid in the pouch of Douglas. A provisional diagnosis of rupture ectopic gestation was established and patient underwent surgery. At laparotomy there was no hemoperitoneum. A left ovarian mass measuring 3.8 cm x 3.2 cm with normal fallopian tube was noted. A left sided oophorectomy was done. Right ovary, fallopian tube and uterus were normal. On gross examination the ovary weighed 30 grams and measured 4.0 cm x 3.5 cm (fig I). The external surface as well as the cut surface was pale in color. Specimen was sent for histopathological examination. On microscopic examination, plenty of chorionic villi lying dispersed in a background of hemorrhagic ovarian stroma were identified (fig II). During follow-up visits she did not report any significant complaint.

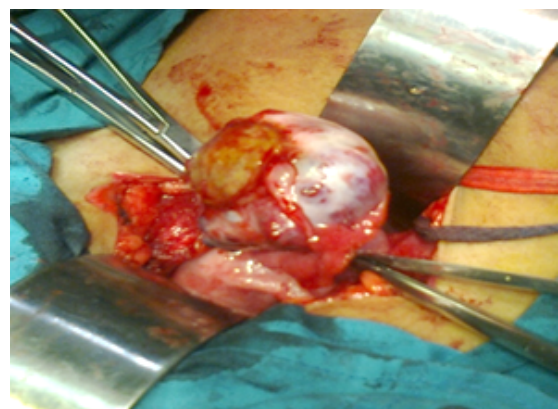


Figure 1. Intact tube with ovarian ectopic seen.

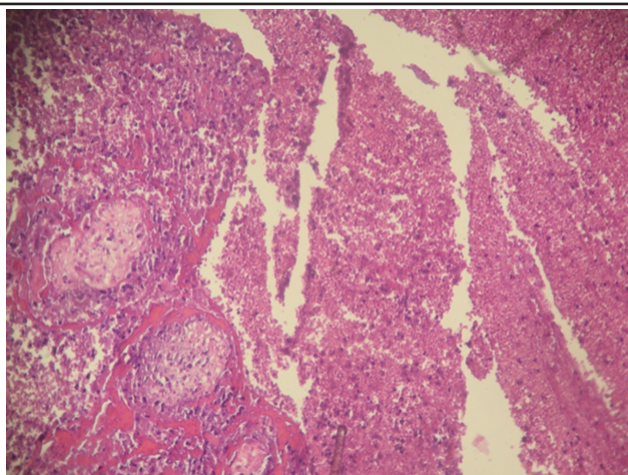


Figure II: Histological diagnosis of ovarian ectopic pregnancy

#### DISCUSSION:

Ovarian ectopic pregnancy was first reported by St. Maurice in 1682.<sup>5</sup> It has two subtypes; intra follicular and extra follicular.<sup>3</sup> In present case report intra follicular ovarian ectopic was recognized. There was no definite identified risk factor present except that patient was on long term injectable contraception. The association of long term injectable contraception with ovarian ectopic pregnancy was not found in literature. However possible mechanism could be fertilization occurring within the follicle following defective ovum release at ovulation due to decreased tubal factor motility. The only risk factor associated with the development of ovarian pregnancy is the current use of intrauterine device.<sup>6</sup> Raziel et al reported that 90% of ovarian pregnancies occurred in intrauterine device users.<sup>7</sup> Ovarian pregnancy mostly occurs in younger age. In contrast our patient was multiparous and of middle age group.

The provisional diagnosis of ovarian ectopic pregnancy in index case was made at laparotomy according to the criteria for diagnosis of ovarian pregnancy proposed by Spiegelberg i.e. ipsilateral tube should be intact and separate from the ovary, the sac must occupy the position of the ovary, it must be attached to the uterus by ovarian ligament and ovarian tissue must be demonstrated in the wall of the sac.<sup>6</sup> Histopathological examination confirmed the diagnosis of an ovarian pregnancy.<sup>8</sup> Although ovarian pregnancy is a rare event, awareness of this condition is important as timely recognition and early referral can reduce mortality and morbidity.

#### REFERENCES:

1. Nadarjah S, Sim LN, Loh SF. Laparoscopic management of an ovarian pregnancy- a

case report. Singapore Med J. 2002;43:95-6.

2. Garg MK, Vyas S, Gulati A, Galwa RP, Khandelwal N. Primary twin ovarian pregnancy: Case report and review of the literature. J Clin Ultrasound. 2009;37:43-6.
3. Gon S, Majumdar B, Ghosal T, Sengupta M. Two cases of primary ectopic ovarian pregnancy. Online J Health Allied Sci. 2011;10:26.
4. Bouyer J, Coste J, Fernandez H, Pouly JL, Job-Spira N. Sites of ectopic pregnancy: A 10 year population-based study of 1800 cases. Hum Reprod. 2002;17:3224-30.
5. Mehmood SA, Thomas JA. Primary ectopic ovarian pregnancy (report of three cases). J Postgrad Med. 1985;31:219.
6. Spiegelberg O-Zur. Cauistik der ovarial schwangerschaft. Arch E Gynak. 1878;13: 73.
7. Raziel A, Golan A, Pansky M, Ronel R, Bukovsky J, Caspi E. Ovarian pregnancy : a report of twenty cases in one institution. Am J ObstetGynecol. 1990;163:1182-5.
8. Ashraf M, Yousaf WA. Ovarian pregnancy: A case report. Proce Sheikh Zayed Postgrad Med Inst. 2000;14:109-10.