

Ectopic Pregnancies at Unusual Locations: Diagnosis and Management With Limited Resources

Sajida Parveen

ABSTRACT

The majority of ectopic pregnancies are located within the fallopian tubes. Nevertheless, pregnancies can be implanted in the cervix, interstitial tubal segment, ovary and at various intra-abdominal sites. The diagnosis and treatment of these unusual implantation sites present both diagnostic and therapeutic dilemmas. The majority of data regarding these unusual ectopic pregnancies came largely from case reports. In the past, for the treatment of these ectopic pregnancies various combinations of surgery and systemic and local chemotherapy were used. In this article, we attempt to share our experience with three unusual types of ectopic pregnancies, their presentation, diagnosis and management with limited resources.

Key words Ectopic pregnancy, Unusual locations, Ultrasound.

INTRODUCTION:

Ectopic pregnancy is amongst the leading causes of maternal mortality.¹ Its frequency in Pakistan is 1:13 pregnancies.² Majority of ectopic pregnancies are located in the fallopian tube. However, pregnancies also occur in cervix, ovary, previous caesarean scar and abdomen.³ Sparse evidence is found in the literature to guide management decisions when ectopic pregnancy is diagnosed at unusual locations.⁴ Advances in ultrasound technology and operator expertise have provided the capability to visualize ectopic pregnancy at unusual location at its earliest stage.⁵ Our experience with three unusual types of ectopic pregnancies are presented in this article. The purpose is to summarize the evidence available for the management of ectopic pregnancies at unusual locations in limited resource setup.

CASE 1:

The patient was a 37 years old, para 4⁺⁰ woman with all previous normal vaginal deliveries. She presented with irregular bleeding over 2-3 weeks following a menstrual delay of 2 weeks and pain in lower abdomen, more on left side. She had history of using intrauterine contraceptive device. Ultrasound

examination revealed an empty uterine cavity with the evidence of 5-6 weeks old gestational sac located eccentrically on the left side of the uterine fundus (Fig I). The gestational sac revealed thin strips of myometrial tissue present superiorly and inferiorly but not laterally. This raised the possibility of interstitial ectopic pregnancy or an extra uterine tubal ectopic pregnancy adjacent to the uterus. She was referred for three dimensional coronal ultrasound scan (3D) which revealed the presence of the gestational sac in the region of left cornua (Fig II). This was suggestive of a high possibility of ectopic pregnancy located in interstitial portion of fallopian tube. She was offered laparoscopic removal of cornual ectopic pregnancy but laparotomy was performed for monetary reasons. Cornual resection and ligation of other tube was performed. She was sent home on 4th post operative day in a satisfactory condition.

CASE 2:

A 32 years old woman, para 2⁺⁰ presented to the emergency room in a state of hypovolemic shock. Ruptured ectopic pregnancy was suspected clinically. There was 12 weeks amenorrhea with a positive urine pregnancy test and fluid was present in abdomen with absence of gestational sac in uterine cavity on two dimensional ultrasound. She was immediately shifted for emergency exploratory laparotomy after resuscitation. Intra-operatively there was massive haemoperitoneum and rupture of right lateral wall of uterus and a 12 weeks foetus and placenta lying freely in

Correspondence:

Dr. Sajida Parveen

Baqai Institute of Reproduction and Developmental Sciences, Baqai Medical University

Karachi

E-mail: safemother@yahoo.com

the peritoneal cavity which was suggestive of right interstitial ectopic pregnancy which had grown up to 12 weeks, invaded the uterine cavity thus forming an angular ectopic. Considering her age and parity, cornual resection was performed. Emergency hysterectomy was avoided due to her two female alive issues only.

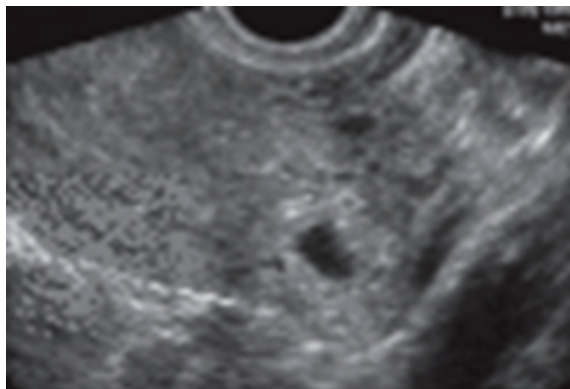


Fig I: Axial 2D US scan at the level of the fundus shows an eccentrically located gestation sac (black arrow) on the left side of the uterine fundus, surrounded by a thin asymmetric myometrium separate from the endometrial cavity.

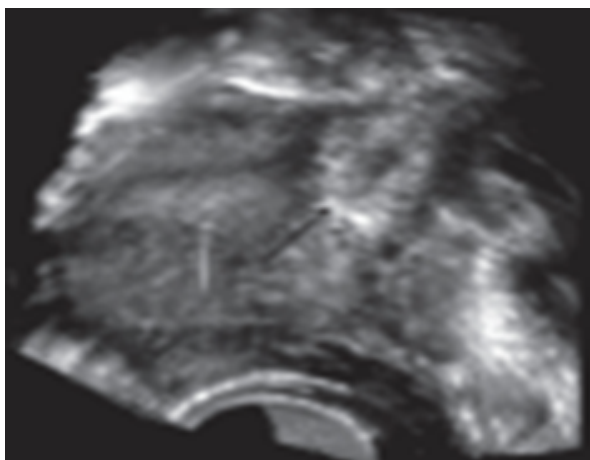


Fig II: Coronal 3D scan shows a gestation sac (black arrow) in the left cornual region separate from the endometrial cavity (white arrow)

CASE 3:

A 30 years old woman, para 1⁺⁰ (history of previous 1 caesarean section) came with history of 5 weeks amenorrhoea and bleeding per vaginum. Her pelvic ultrasound examination revealed a 5 cm gestational sac located within the isthmic area of the lower anterior wall of the uterus, protruding towards the vesico uterine junction (Fig III). She was suspected of caesarean scar pregnancy. Conservative management was planned; however on the development of severe

vaginal bleeding the patient was admitted and dilatation and curettage (D&C) performed. During D & C there was profuse bleeding which was controlled by repeated intravenous injections of synthetic oxytocin (syntocinon) and methyl ergometrine(methergin). Ultrasound was repeated after D&C which revealed residual trophoblastic tissue invading the myometrium up to peritoneum. Single dose of 50 mg methotrexate was given postoperatively. Weekly follow up scan revealed resolution of residual tissue within 4 weeks. She resumed her regular menstrual cycle after complete resolution of ectopic gestation .

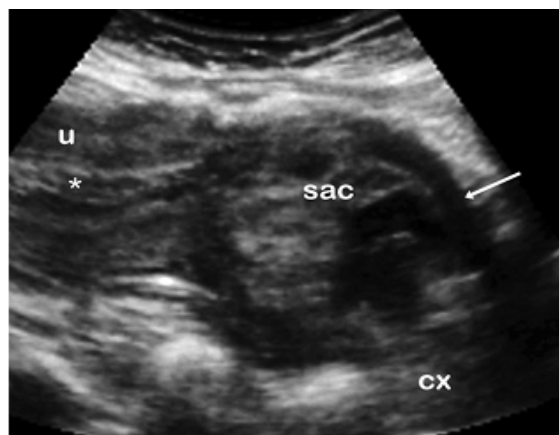


Fig III. Caesarean scar pregnancy. The gestational sac (sac) was located within the isthmus area of the lower anterior wall of the uterus, protruding towards the vesicouterine junction. The endometrium is indicated as (*), uterine-bladder interface (arrow), the cervix (cx) and the uterus (u).

DISCUSSION:

Ectopic pregnancy at any location is a serious problem due to significant morbidity and maternal mortality. Risk of maternal death is increased due to lack of resources at health care facility.⁶ When ectopic pregnancy implants in the cornual segment of uterus, it has a potential to grow further in the area of the fallopian tube surrounding myometrial tissue that allows for further development of pregnancy into second trimester, as happened in case 2 where pregnancy advanced up to 12 weeks of gestation before rupture. Rupture of such an advanced gestation may result in catastrophic haemorrhage with a mortality rate up to 2 %.⁷

Interstitial pregnancy accounts for 1-3 % of all ectopic pregnancies.⁸ Correct diagnosis of ectopic pregnancy can be quite difficult. It requires accurate ultrasound interpretation. Few reports suggest the

utility of 3D transvaginal ultrasound in the diagnosis of interstitial ectopic pregnancy.⁵ In case 1, the diagnosis of interstitial ectopic pregnancy was suggested on 3D transvaginal ultrasonography prior to development of any complication, resulting in early management. The traditional treatment of interstitial pregnancy has been cornual resection or hysterectomy in cases with severely damaged uterus.⁹ However, there are successful case reports of laparoscopic resection of cornual pregnancies.¹⁰ In a survey of 32 cases of interstitial pregnancy, nine required laparotomy for uterine rupture and haemoperitoneum.⁷

Caesarean scar pregnancy is a rare form of ectopic pregnancy with an incidence of 1:1800 pregnancies.¹¹ It is associated with complications such as uterine rupture and massive haemorrhage requiring emergency hysterectomy.¹² This inevitably leads to loss of women's fertility and may have significant long term adverse effects on women's mental and physical health and quality of life. A local report describes successful pregnancy till term after previous caesarean ectopic pregnancy.¹³ Diagnosis of caesarean ectopic pregnancy can be made easily if the sonographer is familiarized with the diagnostic criteria of this situation.¹⁴ As in case 3, caesarean scar ectopic pregnancy was diagnosed early by ultrasound. Optimal treatment of caesarean scar ectopic pregnancy is not agreed upon. Presentation of the patient often dictates the mode of treatment. Systemic use of methotrexate followed by dilatation and evacuation have been described.¹⁵ Treatment of caesarean scar ectopic pregnancy by suction curettage have been described in selected cases.¹⁶ Other treatment options include uterine artery embolization,¹⁷ laparoscopic ligation of bilateral uterine arteries followed by excision of ectopic mass.¹⁸

There have been no prospective studies to compare outcomes of medical and surgical management strategies for ectopic pregnancies at unusual location. Conservative management approaches have been proposed in recent years. The time has come for structured studies that will allow for the objective comparison of surgical and medical approaches to these cases.

CONCLUSION:

Early diagnosis and use of multiple modalities can reduce morbidity and mortality in cases of ectopic pregnancy at unusual location.

REFERENCES:

1. Akber N, Shami N, Anwar S, Asif S. Evaluation of predisposing factors of tubal pregnancy in multigravidas versus primigravidas. *J Surg PIMS* 2002; 25:20 -3.
2. Khawja NP, Rehman R, Durani Z. Ectopic pregnancy at gynaecology Unit 2 Sir Ganga Ram Hospital, Lahore: Study of fifty cases. *Pak J Obstet Gynecol* 1998; 11:61-5.
3. Bouyer J, Coste J, Fernandez H, Pouly JL, Spira N. Sites of ectopic pregnancy: a 10 year population based study of 1800 cases. *Hum Reprod* 2002; 17:3224 -30.
4. Vaesky DV, Yagel S. Ectopic pregnancies of unusual location: management dilemmas. *Ultrasound Obstet Gynecol* 2008; 31:245-51.
5. Araujo jr E, Zanforlin FSM, Pires CR, Guimaraes FHA, Massaguer AA, Nardoza LM, et al. Three dimensional transvaginal sonography of early and asymptomatic interstitial pregnancy. *Arch Gynecol Obstet* 2007; 275:207-10.
6. Shah N, Khan NH. Third delay of maternal mortality in a tertiary hospital. *Rawal Med J* 2007; 32:163-7.
7. Tulandi T, Al Jaroudi D. Interstitial pregnancy: Results generated from the society of reproductive surgeons registry. *Obstet Gynecol* 2004;103:47-50
8. Dilbaz S, Katas B, Demir B, Dilbaz B. Treating cornual ectopic pregnancy with a single methotrexate injection. *J Reprod Med* 2005; 50:141- 3.
9. Katz DL, Barrelet JP, San Filippo JS, Badway DM. Combined hysteroscopy and laparoscopy in the treatment of interstitial pregnancy. *Am J Obstet Gynecol* 2003; 188:1113-4.
10. Moon HS, Choi YJ, Park VH, Kim SG. New simple endoscopic operations for interstitial pregnancies. *Am J Obstet Gynecol* 2000; 152:114-21.
11. Seow K, Hang L, Lin Y. Cesarean scar

11. pregnancy: issues in management .
Ultrasound Obstet Gynecol 2004; 23:247-53.
12. Ben NJ, Ofili YD, Marash M. First trimester cesarean scar pregnancy evolving into placenta previa / accreta at term . J Ultrasound Med 2005; 24:1569 -73.
13. Pregnancy followed by vaginal delivery: in a woman with a previous history cesarean scar ectopic pregnancy. Med Channel 2010; 16:94 -6.
14. Ofili YD, Ben NJ, Sawyer E, Yazbek J, Lee C, Gon-zalez J, Jurkovic D. Deficient lower segment cesarean section scars : prevalence and risk factors. Ultrasound Obstet Gynecol 2008; 31: 72-7.
15. Graesslin O, Dedecker F, Quereux C, Gabriel R. Conservative treatment of ectopic pregnancy in a cesarean scar . Obstet Gynecol 2005; 105:869 -71.
16. Arsalan M, Pata O , Dilek TU , Aktas A, Abas M , Dilek S. Treatment of viable cesarean scar ectopic pregnancy with suction curettage. Int J Gynecol Obstet 2005; 89:163-6.
17. Marchiole P, Gorlero F, Decaro G. Intra-mural pregnancy embedded in a previous cesarean section scar treated conservatively. Ultrasound Obstet Gynecol 2004; 23:305-9.
18. Wang CJ, Yuen LT, Yen CF, Lee CL, Soong YK. Three dimensional power doppler ultrasound diagnosis and laparoscopic management of a pregnancy in a previous cesarean scar. J Laparoendosc Adv Surg Tech A 2004; 14:399-402.