

EDITOR IN CHIEF F.U.Baqai
EXECUTIVE EDITOR Abdul Aziz
EDITOR Asadullah Khan
ASSOCIATE EDITORS Jamshed Akhtar

EDITORIAL BOARD
 Azhar Husain
 Irshad Waheed
 Mohammad Shamim
 Masood Javaid
 Saghir Ahmed
 S.A.Jilani
 Rashid Ahmad Choudhry
 Zahida Baqai

MANAGING EDITOR Abdul Moeed Kazi

EDITORIAL CONSULTANTS

AUSTRALIA Earl R.Owen
BANGLADESH Ahsanullah Chowdhury
 M.Kabiruddin Ahmed
 Humayun Kabir Choudhury

EGYPT Reffat Kamel
INDIA Tehemton E.Udwadia
 Ahmed Abdul Hai
 I.K. Dhawan

JORDAN Ibrahim Bani Bani
NEPAL I.B. Thappa
 A.K.Sharma
 Dharuba Mudavari

REPUBLIC OF Imteyaz Mohsin
MALDIVES A.P.R. Aluwihare
SRI LANKA John Hadfield
U.K. J.S.P. Lumley

U.A.E. Essa Kazim
PAKISTAN Abdullah Jan Jaffar
 Adib ul Hasan Rizvi
 Changez Hakim Khan
 Faiz Mohammad Khan
 Ghulam Ali Memon
 Ijaz H. Aqeel
 Altaf H. Rathore
 Jan Mohammad Memon
 M. Azhar Chaudhry
 Muhammad Iqbal
 Moizuddin
 M. Younis Khatri
 M. Naeem Khan
 Shabeer Hussain
 Shah Nawaz Shah
 Sikander Shaikh
 Syed Azhar Ahmed
 Tariq Saeed Mufti
 Tipu Sultan
 Z.K.Kazi
 Zafarullah Chaudhry

Approved by the
Pakistan Medical & Dental Council
 &

**Index Medicus for the Eastern
 Mediterranean Region**

Published by: Prof. Abdul Aziz for
 Prof. F.U. Baqai, Baqai Postgraduate
 Medical Institute, IIIC, 1/12, Nazimabad,
 Karachi

Address for correspondence:
 Prof. Abdul Aziz, Executive Editor JSP
 C/o Treasurer,
 College of Physicians and Surgeons Pakistan,
 7th Central Street, DHA, Karachi-75500

Subscription rates: Per copy-in Pakistan
 Rs. 100/= in SAARC countries U.S. \$20, in
 other countries U.S. \$30, Annual- in
 Pakistan Rs. 300/= in SAARC countries US
 \$ 60, in other countries U.S. \$90.

Layout by: Aleemuddin Siddiqui
 Madad Ali Channa

VOL. 8 NO. 1 (JANUARY - MARCH 2003)

QUARTERLY

JSP

**JOURNAL OF
 SURGERY
 PAKISTAN
 INTERNATIONAL**

EDITORIAL

Importance of Monitoring of Training Asadullah Khan 1

ARTICLES

Surgery for the Assault Patients Tahir Ali 2

Effects of diazepam and promethazine
 on uterine contractions induced by
 prostaglandin E₂ (PGE₂) Sibghatullah Sangi 6

Vesicovaginal Fistulae: A surgical outcome Rafia Baloch 10

Correlation of CT Scan and Histopathology
 in brain tumors Malik Muhammad Khalid 14

Basal Cell Carcinoma Hafeezullah Abro 19

Topical application of glyceryl trinitrate
 0.2% for fissure-in-ano Muhammad Yousuf 22

Efforts to reduce Caesarean section rate Sohail Mahmood Ch. 25

CASE REPORTS

Trichobezoar and Gastric Polyps:
 A rare association Abdul Qadeer 28

Xanthogranulomatous Pyelonephritis
 in a child Aurangzeb Khan 30

Unusual presentation of
 Hydronephrosis Muhammad Zarin 32

Right Inguinal region Lipoma Mubashir Hussain Sherazi 34

IMPORTANCE OF MONITORING OF TRAINING

It is now realized and accepted by all that the most essential component of making a surgeon is standardized, objective oriented and competencies based training which should be supervised, observed and recorded. The produce of the training should be performed based. supported by evidence.

Learning skills by Hit and trial method with no standardization and without any realization of the results of techniques is out question.

It is also extremely essential to look into the Ethical issues involved in training and teaching. The rights of the patients must be protected at all cost. Hence direct supervision by trained masters is essential. The master trainers are unfortunately extremely busy and are over worked They are the ones who are sucked into administration, Planing and policy making by the authorizes resulting in the tendency to ignore the direct supervision of training of the trainees as it becomes very difficult for them to priorities their schedule and manage time. Monitoring though not very desirable and difficult to implement should be mandatory. One needs lot of coverage, planning, understanding and hard work to prepare the masters to accept policing. But some one has to do this job convincingly and boldly, without any compromise, because this is the only way to achieve the objective of providing the society with reliable, confidant and good professionals who can deliver acceptable scientific health care.

The training should be monitored, performance based, competencies oriented, supported by recorded evidence, documented, safe and scientific. To achieve the objective of providing best possible health care to the society by properly qualified and trained doctors and specialists. The authorities at all levels, government. universities and training institution must be aware of the present day health care demands, issues and requirements of the societies and communities, who will be the end users of these qualified professionals The whole senerio should be first scientifically studied, assessed and evaluated in the light of the objective of the training. Strategies of achieving the objective should be planned and implemented making best use the available resources and manpower.

The objectives should be attainable, plans workable and sensible with the end results in mind with a clear picture and map to work on and at no stage ignoring the rules of monitoring uncompromising, strict and action oriented. And with the proper monitoring perhaps we may acquire the competency of providing our country good health care system.

ASADULLAH KHAN

RECEIVED
10/10/2011
10/10/2011
10/10/2011

SURGERY FOR THE ASSAULT PATIENTS

TAHIR ALI

ABSTRACT:

One hundred ninety nine patients were included in this study of one year duration. There were 177 males and 22 females. The mean length of hospital stay of the 16 most seriously injured patients (ISS scores of more than 15) was 7 days. The head was the principal area to be injured. The head region sustained 132 injuries (41% of all injuries) and four cranial operations (3% of injuries to the head) were performed. The maxillofacial region required most surgical operations. Twenty-three facial operations (39% of all operations) were performed. The ratio between operations and injuries was highest for the lower limb and the lowest for the cranium. There were 14 injuries to the lower extremity and 10 lower limb operations (72% of injuries to lower limb) were performed. Fifty-three patients (26.6% of total) required operations. There was one death of a woman of 88 years of age with an ISS score of 9 and her death was largely due to post-operative complications.

KEY WORDS: Assault, Surgery, Complications.

INTRODUCTION

Injuries may be characterized in terms of soft tissue and bony injuries. Bruises, contusions, ecchymosis, haematomas and lacerations can occur anywhere but commonly involve the face in the UK assault, as do fractures.¹⁻⁹ studies carried-out in Britain have shown that approximately two-thirds of all lacerations and slightly less than two thirds of all haematomas after assault affect the face. The second most common site of injury in assault in Britain appears to be the upper limb, probably because many victims struck their assailant and injured their hands by doing so. Less frequent are chest and other head and neck injuries. The least affected area is the abdomen.

Inter-personal violence is perhaps the most common cause of fractures of facial skeleton in Western Europe¹⁰. The most common fractures are nasal fractures, followed by mandibular and zygomatic fractures. Le Fort pattern fractures are rarely seen.¹¹

Because there have been no published studies concerning injuries and operations in assault patients admitted to hospital in Britain, the aim of this study was: To characterize the injuries sustained by the in-patients in terms of anatomical region and operation rate.

.....
Correspondence:
Dr. Tahir Ali
Associate Professor
Baqai Dental College, Baqai Medical University
Karachi.

PATIENTS AND METHODS

In this study, in-patient records in relation to all assault patients who attended the Bristol Royal Infirmary (BRI) between 1st January 1989 and 31st December 1989 were scrutinized. The hospital has the sole A & E department serving central and south Bristol, and a large rural area to the south of the city.

Number of assault patients who were admitted within 24 hours of injury were recorded by gender, severity of injury, date of admission and discharge, date of birth, diagnosis and operation(s) required. Number of patients with ISS scores¹² of more than 15 were identified and the information about this particular group are presented separately in view of the fact that care in a specialized trauma unit has been recommended for this group of patients.^{13,14}

Injuries and number of operations performed to repair each body region were calculated. In this study, to simplify the relationship between injuries affecting particular body regions and operations performed in each body region, injuries were recorded as one injury per body region in cases where one body region sustained multiple injuries. For example, if a patient's injuries included facial lacerations, facial haematomas, a fracture of the mandible and a fracture of neck of femur, only one injury of the face and one injury of the lower extremity were recorded. Body regions were divided according to the Abbreviated Injury Scale method.¹⁵ An operation was defined as a surgical procedure carried out under general

anaesthesia. However, operations were identified in this study as they were recorded for the Major Trauma Outcome Study (MTOS).

RESULTS

The head region sustained 132 injuries (41% of all injuries) but only four cranial operations (for 3% of injuries to the head) were performed. The face sustained 100 injuries (31% of all injuries) and 23 facial operations (39% of all operations) were performed. No neck injuries occurred. There were three spinal injuries (0.9% of all injuries) and no spinal operations were performed. Fifteen abdominal injuries (4.6% of all injuries) were recorded and six abdominal operations were performed (10% of all operations; 40% of abdominal injuries required operative intervention). The upper extremity sustained 30 injuries (9.3% of all injuries), and 14 operations were performed (23% of all operations; 47% of injuries of the arm and hand required operative intervention). There were 14 injuries of

the lower extremity (4.4% of all injuries) and 10 lower limb operations were performed (17% of all operations; 72% of injuries of the lower extremity required operative intervention). There were five other injuries (1.6% of all injuries) including burns and contusions, and one operation was carried out for burns at the local burns unit. Fifty-three patients (26.6% of total) needed operations and four patients needed more than one operation. (Table-I)

Among the 16 patients who had ISS scores of more than 15, five patients did not require surgical intervention. About 50% of severely injured patients (ISS scores of more than 15) had severe injuries to the head region. Only three patients required management in the Intensive Therapy Unit and their mean hospital stay was 7 days (Table-II).

There was one death recorded of a woman aged 88 years who had an ISS score of 9 following blunt trauma. A fracture of neck of femur and fracture of radius were found.

TABLE-I NUMBER OF INJURIES IN IN-PATIENTS BY BODY REGION AND OPERATION

Body region	Number of Injuries (%)	Number of Operations (%)
Head	132 (40.9)	4(7)
Face	100 (30.9)	23 (39)
Neck	0	0
Thorax	24 (7.4)	1 (2)
Abdomen	15 (4.6)	6(10)
Spine	3 (9.3)	14 (23)
Upper Extremity	30 (9.3)	14 (23)
Lower Extremity	14 (4.4)	10 (17)
External Burns etc.	5(1.6)	1(2)
Total	323(100)	59(100)

DISCUSSION

There were only 16 patients with an ISS score of more than 15. One study carried out in the UK suggested that only about 4% of trauma patients who are admitted to hospital have ISS scores of more than 15¹⁶. These results confirm that few patients will need care in any dedicated trauma care unit with ISS scores of more than 15.

The difference in mean length of stay between patients with intentional injuries and patients with road related injuries is clear. Mean hospital stay of patients with severe

TABLE-II CHARACTERISTICS OF ADMITTED ASSAULT PATIENTS WITH INJURY SEVERITY SCORES OF MORE THAN 15

S.No.	ISS Scores	Age	Gender	Type of Injury	Hospital Days	ITU Days	Body region affected
1.	12	35	M	P	8	2	Abdomen
2.	17	21	M	B	8	-	Head
3.	17	24	M	B	10	-	Face
4	17	26	M	B	6	-	Head
5.	17	40	M	B	7	-	Lower Extremity
6.	17*	74	M	B	7	-	Head
7.	18	16	M	P	6	-	Lower Extremity
8.	20	22	M	P	9	-	Upper Extremity
9.	21	32	F	P	15	-	Upper Extremity
10.	21*	37	M	B	4	-	Abdomen
11.	22*	28	M	B	2	2	Head
12.	22*	46	M	B	6	-	Head
13.	25	25	F	P	9	-	Abdomen
14.	26*	20	M	B	3	-	Head
15.	29	23	M	P	14	4	Abdomen
16.	29	35	M	P	5	-	Head

P= Penetrating B= Blunt * = Patients did not require operation

road related injuries (ISS score range 15-24) has been found to be 45.7 days (17) and in this study, mean length of in-patient stay was only 7 days for those with similar ISS scores (range: 16-29).

Surprisingly, in this study, there were no neck injuries, while the head was the most frequent site of injuries overall. The low number of operations carried out on the head suggests that nearly all head injuries were comparatively minor and therefore that surgery was not indicated. One out of the total of four operations carried out on the head was simple suturing of an extensive laceration. The remaining three cranial operations, which were all performed on patients with ISS scores of more than 15, comprised repair of cerebral laceration, elevation of fractured skull and evacuation of extradural haematoma. Nearly all patients with head injuries and about 75% of patients did not require any operation to any region, the most important reason for admission in this series was observation. The indications for admission after head injury are 1%.

- 1) Any degree of depression of level of consciousness on examination
- 2) Skull fracture
- 3) Focal neurological signs
- 4) Persistent headache and vomiting
- 5) Other medical conditions such as anticoagulant therapy or hemophilia.
- 6) Uncertainty about the degree of alcohol intoxication
- 7) Absence of responsible relatives or friends at home.

The comparatively large number of maxillofacial operations confirms that the face was more susceptible to debilitating and deforming injuries than the cranium. Frequent injuries comprised fractures of the mandible, zygoma, nose or orbit, whether alone or in combination. It may be that assailants select the face as the main target area because it is more vulnerable, and select the rest of the head less often. A more likely explanation is that the face is comparatively much more fragile, and not able to withstand forces, except those brought about by mastication. These results show that proportionately more limb operations were performed on patients with ISS scores of less than 16. The same was true for the maxillofacial region where most of the operations were performed on less severely injured patients. Only a few patients who sustained injuries to the lower limb did not require an operation.

It was interesting to note that all of the patients who required abdominal operations were injured by a penetrating weapon, and it is also interesting to note that only one out of six abdominal operations was performed for a patient who had an ISS score of less than 16. One patient required two operations. This reflects that the

abdomen is comparatively more vulnerable to penetrating injury and an operation is usually necessary. Conversely, serious head injuries are more likely to be due to blunt injuries.

Injury Severity Scores (ISS) have been found to correlate better with mortality than AIS scores, and an ISS score of 16 or more is predictive of 10% mortality.¹³ The only patient in this series who died had an ISS score of only 9, but death was primarily due to bronchopneumonia and osteoporosis. Increased bone fragility is an established indirect cause of premature death, where fractures are more likely, particularly in women. Deaths among the most severely intentionally injured patients in Britain are rare, as evidenced by this study and by WHO statistics on homicide. Cause of death includes not only the injuries themselves, but also postoperative problems. Nevertheless, the one patient in this series who died had a fracture of neck of femur and a fracture of the radius and illustrates why they mortality rate due to fracture of neck of femur has been reported as approximately 20%.¹⁸

CONCLUSIONS

1. Among these in-patients, head injuries were the most frequent.
2. Surgical intervention was necessary most often in the maxillofacial region
3. The rate of surgical intervention was highest for lower limb injuries and lowest for head injuries.
4. Mortality was very low in in-patients whose injuries were intentional.

REFERENCES

1. Haider Z. Fracture of zygomatic complex in the south east region of Scotland. *Br J Oral Surg* 1978;15:265.
2. Van Hoof RF, Merckx CA, Stekelenberg C. The different patterns of fractures of facial skeleton in four European countries. *Inter J Oral Surg* 1972;6:3.
3. Anderson L, Hulfin M, Nordenram A, Ramstrom G. Jaw fractures in the country of Stokholm (1978-1980) *Inter J Oral Surg* 1984;13:194
4. Hill CM, Crosher RF, Carrol MJ, Mason DA. Facial fractures: the result of a prospective four year study. *J Max Surg* 1984;13:194.
5. Katz RV, Barnes GP, Larson HR, Lyon TC, Brunner DG. Epidemiologic survey of accidental dentofacial injuries among US army personnel. *J Comu Dent Epidem* 1979;7:30.
6. Lamberg MA. Maxillofacial fractures. *Proceedings of the Finnish Dental Society (supplement)* 1978;74:7
7. Brook LM, Wood N. Aetiology and incidence of facial fractures in adults. *Inter J Oral Surg* 1983;12:193.
8. Voss R. Changing aetiologic pattern of jaw fractures. In *Maxillofacial trauma: An international prospective*. Jacobs JR (Ed) New York: Praeger 1983.

9. Neal DC, Wagner WF, Alpert B. The epidemiology of facial fractures. *J Kent Med Assoc* 1978;76:275.
10. Rowe N, Williams J: Maxillofacial injuries. Churchill Livingstone, London 1985 999-1008.
11. Shepherd JP, Shapland M, Pearce NX, Scully C. Pattern severity and aetiology of injuries in victims of assault. *J Royal Soc Med* 1990;83:75-78.
12. Ali T, Shepherd JP. The measurement of injury severity. *Br J Oral Max Surg* 1994;12:13-18.
13. Boyd CR, Tolson MA, Copes WS. Evaluating trauma Care: The TRISS method. *J Trauma* 1987;27:370-378.
14. Smith EJ, Ward AJ, Smith D. Trauma scoring methods. *Br Hosp Med* 1990;44:114-118.
15. Abbreviated Injury Scale Revision. Des Plaines, Illionis. Association for the advancement of automotive medicine, 1990.
16. Rutherford WH. Reception of severely injured patients at hospital: Organisational requirements. *Injury* 1990;21:344-346.
17. Bull JP. The Injury Severity Score of road traffic casualties in relation to mortality, time of death, hospital treatment time and disability. *Accid Anal & Prev* 1975;7:249-255.
18. Rains AJH, Mann CV. Baily and Love's Short practice of surgery. London 1988.

.....★.....

EFFECTS OF DIAZEPAM AND PROMETHAZINE ON UTERINE CONTRACTIONS INDUCED BY PROSTAGLANDIN E₂ (PGE₂)

SIBGHATULLAH SANGI, KAUSAR AAMIR, JAMAL ARA, SAEED A.MAHAR

ABSTRACT:

This study was conducted at Basic Medical Sciences Institute, Jinnah Post Graduate Medical Center, Karachi. It was done to observe the inhibitory effects of diazepam and promethazine, on uterine contractions induced by prostaglandin E₂ (PGE₂). The drug interaction, in vitro, proved that both diazepam and promethazine are tocolytic in vitro.

KEY WORDS: *Diazepam, Promethazine, Prostaglandin E₂ (PGE₂), Tocolysis.*

INTRODUCTION

Pregnancy is a physiological process which encompasses implantation of embryo in the womb, after fertilization in the fallopian tubes. It continues for about 37 calendar weeks i.e. from conception to parturition.¹ During this period several changes occur in the maternal anatomy and physiology like increase in ACTH, cortisol, angiotensin and aldosterone levels.² All these changes cause increase in blood volume leading to increase in pre and after cardiac load giving rise to hypertension.³ If hypertension is left untreated in pregnancy convulsions may develop along with proteinuria and edema. The condition is then termed as eclampsia. It has been estimated that world wide approximately 50000 women die each year from eclampsia.⁴ Eclampsia is most common in the last trimester and becomes increasingly more frequent as term approaches⁵.

Termination of pregnancy is nowadays brought about by use of PGE₂ pessaries.⁶ PGE₂ pessaries are preferred for their less side effects than systemic side effects of oxytocin and to avoid complications of anaesthesia in caesarean section. The plasma half life of most prostaglandins in the circulation is about two minutes. The prostaglandin specific enzymes metabolise PGE₂ are present in high concentration in the lung, and 95% of PGE₂ or PGF₂ is inactivated on first passage.⁷ there are three sub groups of receptors for PGE₂ termed EP₁, EP₂ and EP₃.

By acting at EP₃ receptors, it causes contraction of intestinal smooth muscle, inhibition of gastric acid

.....
Correspondence:
Dr. Sibghatullah Sangi
Pharmacology and Therapeutic Department
MBSI, JPMC, Karachi.

secretion, increased gastric mucus secretion, inhibition of lipolysis, inhibition of autonomic neurotransmitter release and stimulation of contraction of pregnant uterus⁸.

Anticonvulsants used in eclampsia worldwide are magnesium sulphate, diazepam and phenytoin of which diazepam is the most common anticonvulsant being used world wide⁹. Diazepam is used alone or in combination with promethazine. Half life of diazepam parent compound is 20-40 hours, active compounds are desmethyl diazepam, oxazepam and temazepam and half life of metabolites is 60 hours. Overall duration of action is long i.e. 29-48 hours¹⁰. It acts by opening the GABA mediated chloride ion channel opening¹¹.

Promethazine is one of the important members of phenothiazine group. These are usually considered as first generation antihistamines. Promethazine blocks D1, D2, adrenergic, H₁ muscarinic, ACH and 5 HT₂ receptors. Its duration of action is 4-6 hours following a single dose¹².

The purpose of the study was to evaluate the extent to which anticonvulsants affect the myometrial contractions produced by Prostaglandin E₂, used commonly for induction of labour.

MATERIAL & METHODS

Twenty four full term pregnant albino rats of Sprague Dawley strain were used in the present study. They were supplied by the animal house of Jinnah Postgraduate Medical Center Karachi.

Drugs used were

1. Prostaglandin E₂ solution (Sigma)
2. Injection valium (Diazepam, Roche)
3. Injection Phenergan (Promethazine, Rhone-Poulanc Rorer)

DeJalon's solution was used as a nutrient fluid for uterine tissue for tracing on polygraph machine.

A full term pregnant rat (between day 22-25) was killed by blow on the head. The abdomen was opened by midline incision and intestine placed on one side. Fetus removed and uterus was freed from its ligaments and fat. The whole uterus was then transferred to petridish containing oxygenated De-Jalon's solution. A piece of about 25mm was cut from the middle portion of one horn of uterus. One end of the tissue was attached with the hooked lower end of the glass rod by means of thread, while the other end of the tissue was attached to the forced displacement transducer connected to the polygraph and was subjected to the tension of 0.5 gram. The nutrient solution was oxygenated (95% oxygen and 5% carbondioxide). Temperature of organ bath was maintained by thermostat at 37°C. The pH of bath fluid was maintained at 7.4. The tissue was allowed to equilibrate in the organ bath for half an hour, till the activity became reasonably stable. The tissue, which showed irregularities in its activity was discarded¹⁴.

METHODOLOGY OF EACH EXPERIMENT

1. In first group, after mounting the tissue in organ bath, it was left for half an hour to equilibrate. Then normal contractile response of isolated ripened uterine preparations was recorded for 15 minutes. This was taken as control group.
2. In 2nd group different dilution of PGE₂ was used. The concentration which gave maximum response came out to be 1mg/ml. It was taken as standard dose and was used in further study.
3. Six animals were pre treated with diazepam 1.5mg intraperitoneally. After two hours it was sacrificed, uterus was removed, both horns were exposed individually to PGE₂ and effects were recorded on the graph paper.
4. Six animals were pretreated with promethazine 3mg intraperitoneally. After two hours it was sacrificed, uterus removed, both horns exposed individually to PGE₂ and effects were recorded on graph paper.
5. Diazepam 1.5mg plus promethazine 3mg were injected intraperitoneally. After two hours animal was sacrificed, uterus isolated and exposed to PGE₂. Effects were recorded on the graph paper. Readings were recorded on the above mentioned pattern.

RESULTS

1. Effect of 1 mg/ml PGE₂ on isolated ripened uterine preparation of rat.

CONTROL GROUP

- A) Rate of spontaneous contractions of 15 minutes was recorded. Six experiments were performed. The mean value of spontaneous contraction was 6.5(0.22), after exposure to PGE₂ 1 mg/ml, mean value was increased to 10(0.25). This difference was statistically highly significant.
- B) The amplitude of contraction was measured in centimeters (cms). It showed a rise in the height as compared with the control. The mean value of control was 3.45(0.05.) After exposure to PGE₂ 1 mg/ml, the height rose to a mean value of 4.4(0.07). This difference was statistically highly significant (P<0.001).

Total Twenty-four experiments were performed for this study. 1 mg/ml of PGE₂ caused a 21.6% (P < 0.001) rise in amplitude and 34.96% (P < 0.001) increase in the rate of contractions of a full term pregnant isolated uterus.

In tissue pre-treated with diazepam 1.5 mg, 1 mg/ml PGE₂ increased the rate of contractions to 10.92% (P < 0.001) and raised the amplitude by 5.6% (P < 0.001).

In the isolated uterus of a rat pretreated with promethazine 3 mg, PGE₂ 1 mg/ml caused an increase of 7.19% (P < 0.001) in rate of contractions and 13.45% (P < 0.001) raise in amplitude of contractions.

1 mg/ml of PGE₂ increased the rate of contractions to 23.67% (P < 0.001) and amplitude of contractions to 20.33% (P < 0.001).

In the group pre-treated with diazepam 1.5mg and promethazine 3mg, PGE₂ caused an increase of 20.33% (P < 0.001), and 23.67% (P < 0.001) in amplitude and rate of contractions respectively.

This study shows that promethazine was more inhibitory than diazepam by a factor of 45.59% and 53.50% in rate and amplitude of contractions respectively.

TABLE-I EFFECTS OF PGE₂ (1 mg/ml) ON THE AMPLITUDE OF CONTRACTIONS ON ISOLATED UTERINE MUSCULATURE OF RAT

	Amplitude of contractions in cm		P value	Percentage (%)
	Control	PGE ₂		
Mean	3.45	4.4		
SD	0.13	0.18		21.6%↑
	± 0.05	± 0.07	11.04	
	(6)	(6)	<0.001	

TABLE-II EFFECTS OF PGE₂ (1 mg/ml) ON RATE OF CONTRACTION ON ISOLATED UTERINE MUSCULATURE OF RAT

	Rate of contractions per 15 minutes		P value	Percentage (%)
	Control	PGE ₂		
Mean	6.5	1.0		
SD	0.54	0.63	10.50	34.96%↑
	± 0.22	± 0.25		
	(6)	(6)	<0.001	

Each value represents mean of total observations.
 SD = Standard deviation
 ± Represents Standard error.
 Figures in parenthesis indicate the number of observations.
 P value between control and PGE₂

TABLE-VI EFFECTS OF PGE₂ (1 mg/ml) ON THE RATE OF CONTRACTIONS ON ISOLATED RIPENED UTERINE MUSCULATURE OF RAT PRETREATED WITH PROMETHAZINE (3 mg)

	Rate of contractions		P value	Percentage (%)
	Promethazine	PGE ₂		
Mean	98.66	9.33		
SD	1.21	4.17	0.93	7.19%↑
	± 0.20	± 0.69		
	(6)	(6)	<0.001	

Each value represents mean of total observations.
 SD = Standard deviation
 ± represents Standard error.
 Figures in parenthesis indicate the number of observations.
 P value between control and PGE₂

TABLE-III EFFECTS OF PGE₂ (1 mg/ml) ON THE AMPLITUDE OF CONTRACTIONS ON ISOLATED RIPENED UTERINE MUSCULATURE OF RAT PRETREATED WITH DIAZEPAM (1.5 mg)

	Amplitude of contractions in cm		P value	Percentage (%)
	Diazepam	PGE ₂		
Mean	2.70	2.86		
SD	0.08	0.08	11.31	5.60%↑
	± 0.01	± 0.01		
	(6)	(6)	<0.001	

TABLE-IV EFFECTS OF PGE₂ (1 mg/ml) ON THE RATE OF CONTRACTIONS ON ISOLATED RIPENED UTERINE MUSCULATURE OF RAT PRETREATED WITH DIAZEPAM (1.5 mg)

	Rate of contractions		P value	Percentage (%)
	Control	PGE ₂		
Mean	8.16	9.16		
SD	1.16	1.16	3.72	10.92%↑
	± 0.19	± 0.179		
	(6)	(6)	<0.001	

Each value represents mean of total observations.
 SD = Standard deviation
 ± represents Standard error.
 Figures in parenthesis indicate the number of observations.
 P value between control and PGE₂

TABLE-VII EFFECTS OF PGE₂ (1 mg/ml) ON THE AMPLITUDE OF CONTRACTIONS ON ISOLATED RIPENED UTERINE MUSCULATURE OF RAT PRETREATED WITH DIAZEPAM (1.5 mg) AND PROMETHAZINE (3 mg)

	Amplitude of contractions in cm		P value	Percentage (%)
	Diazepam Promethazine	PGE ₂		
Mean	2.43	3.05		
SD	0.08	0.108	43.84	20.33%↑
	± 0.01	± 0.01		
	(6)	(6)	<0.001	

TABLE-VIII EFFECTS OF PGE₂ (1 mg/ml) ON THE RATE OF CONTRACTIONS ON ISOLATED RIPENED UTERINE MUSCULATURE OF RAT PRETREATED WITH DIAZEPAM (1.5 mg) AND PROMETHAZINE (3 mg)

	Amplitude of contractions in cm		P value	Percentage (%)
	Diazepam Promethazine	PGE ₂		
Mean	7.16	9.38		
SD	1.16	1.47	48.72	23.67%↑
	± 0.19	± 0.24		
	(6)	(6)	<0.001	

Each value represents mean of total observations.
 SD = Standard deviation
 ± represents Standard error.
 Figures in parenthesis indicate the number of observations.
 P value between control and PGE₂

TABLE-V EFFECTS OF PGE₂ (1 mg/ml) ON THE AMPLITUDE OF CONTRACTIONS ON ISOLATED RIPENED UTERINE MUSCULATURE OF RAT PRETREATED WITH PROMETHAZINE (3 mg)

	Amplitude of contractions in cm		P value	Percentage (%)
	Promethazine	PGE ₂		
Mean	2.15	2.9		
SD	0.17	0.14	13.78	13.45%↑
	± 0.02	± 0.02		
	(6)	(6)	<0.001	

TABLE-IX COMPARISON OF DIFFERENT DRUGS WITH THE CONTROL ON THE RATE OF CONTRACTION OF ISOLATED RIPENED UTERINE MUSCULATURE OF RAT

Control	PGE ₂ (1mg/ml)	Diazepam (1.5 mg/ml)	Promethazine (3 mg/ml)	Diazepam 1.5 mg/ml + Promethazine 3 mg/ml
6.50	10.00	8.16	8.66	7.16
± 0.22	± 0.25	± 0.19	± 0.20	± 0.19
(6)	(6)	(6)	(6)	(6)

TABLE-X COMPARISON OF DIFFERENT DRUGS WITH THE CONTROL ON THE AMPLITUDE OF CONTRACTION OF ISOLATED RIPENED UTERINE MUSCULATURE OF RAT

Control	PGE ₂ (1mg/ml)	Diazepam (1.5 mg/ml)	Promethazine (3 mg/ml)	Diazepam 1.5 mg/ml + Promethazine 3 mg/ml
3.45	4.40	2.70	2.51	2.43
± 0.05	± 0.07	± 0.01	± 0.02	± 0.01
(6)	(6)	(6)	(6)	(6)

Each value represents mean of total observations.

± represents Standard error.

Figures in parenthesis indicate the number of observations.

P1 value between control and PGE₂

P2 value between PGE₂ and Diazepam.

P3 value between PGE₂ and Promethazine.

P4 value between PGE₂ and Diazepam + Promethazine

DISCUSSION

A great majority of neonatal and maternal deaths occur due to complications of pregnancy. The mortality rate can be reduced by adequate antenatal care with active treatment of factors that predispose to complications like eclampsia. The process of inhibition of myometrial contraction is termed as tocolysis. Many drugs have tocolytic effects like B-receptor agonists ritodrine, terbutaline and salbutamol. Other tocolytics include magnesium sulfate, calcium channel blockers, sedatives, nitric oxide, etc¹⁵. Diazepam is a centrally acting inhibitory drugs in animals. Peripheral benzodiazepine receptors are also found in esophagus, heart, intestine and urinary bladder where it produces decrease in heart rate¹⁶, retention of urine, constipation, and relaxation of esophagus. Promethazine belongs to phenothiazine group. It has wide variety of actions like antimotion sickness effect, antipsychotic effect and anticholinergic effect etc.

Diazepam and promethazine are widely used in obstetric practice, but no data is available about their effects on uterine muscle. Results of this study show that the uterine contractions induced by PGE₂ are significantly reduced by diazepam and promethazine.

CONCLUSIONS

Having different mode of actions from PGE₂, the reduction in number of contractions as well as in amplitude of contractions gives clue that both diazepam as well as promethazine are tocolytic in rats. However, the results of

this study should be verified before concluding that these drugs may also affect uterine contractions in humans too.

REFERENCES

1. Dorland's Illustrated Medical Dictionary. 27th Ed. W.B.Saunders Company, 1998; 190.
2. Guyton AC. Basic human physiology, female physiology before pregnancy and the female hormones. 1996; Chap. 81, pp.899-913.
3. Redman CWG. Eclampsia still kills. Br. Med. J. 1988;296.
4. Duley. L. Maternal mortality associated with hypertensive disorders of pregnancy in Africa, Asia, Latin America and the Caribbean. Br J Obstet. Gynaecol. 1992; 99:547-553.
5. Dewhursts Textbook of Obstetrics and Gynaecology for Postgraduates. 5th edition, Blackwell Science Ltd. Cambridge, 1995; 175-215.
6. Baha MS, Thomas NA, Joseph AS, Garland DA. Eclampsia. Am J Obstet.Gynecol. 1986; 155:153-154.
7. Mainprize T, Nimrod C, gail Dod RN, Persaud D. Clinical utility of multiple dose administration of postaglandin E2 gel. Am J Obstet. Gynecol 1987; 156: 341-3.
8. Coleman RA, Smith WL, Narumiya S. Eight International Union of Pharmacology. Classification of prostanoid receptors: Properties, distribution and structure of the receptor and their subtypes. Pharmacol Rev. 1994; 46:205.
9. Bennett PR, Rose MP, Myatt L, Elder MG. Preterm labour: Stimulation of arachidonic acid metabolism in human amnion cells by bacterial products. Am J.Obstet Gynecol. 1987; 156:649-55.
10. Duley L. The must – Read Trial:Eclampsia, 1995;pp.17-25.
11. Patricia MK. Gerhard L. Kinetics of drug action in disease states XXIV Pharmacodynamics of diazepam and its active metabolites in rats. J. Pharmacol Experiment Ther. 1988; 244,1.
12. Jeremy JL, Brieli D, Hillvenning C, John AP. Neurosteroids and GABA receptors function. Trends in Pharmacological Sciences, 1995: 16.
13. Goodman, AG Goodman and Gillman's The Pharmacological basis of therapeutics. 9th Ed. McGraw Hill., 1996;303, 403, 490, 588, 591, 592, 930.
14. Mahesar AL. Tocolytic effects of different drugs, M.Phil Thesis, University of Karachi, 1995.
15. Calvin Turnbull Textbook of Obstetrics 2nd Ed. Appleton and Lange, 1988; pp. 693-735.
16. Nakee Y, Kanaya N, Namiki A. The direct effects of diazepam and midazolam on myocardial depression in cultured rat ventricular myocytes. Anesth Analg. 1997; 85:729-33.



VESICOVAGINAL FISTULAE: A SURGICAL OUTCOME

RAFIA BALOCH, HAFEEZULLAH, MALIK JALBANI, RAJIB DENARI

ABSTRACT:

The aim of this study was to know sociodemographic data and causes of failure of surgical procedure for vesico vagina fistulae so that a better methodology be applied to improve the results. This study was conducted at Shaikh Zayed Women Hospital, (Gynaecology and Obstetrics Department) Chandka Medical College, Larkana from May 1997 to May 2002 Seventy patients of vesicovaginal fistula (VVF) were managed in 5 years. Patients with stress incontinence, urgency and over flow incontinence were excluded. The age, parity, duration of fistula, causes of fistula, size, site of fistula, route of operation, type of operation, duration of operation, blood loss and results of surgery were recorded.

The total admissions with gynaecological ailment were 4768 in five years. The relative frequency of VVF cases was 1.4%. The mean age was 34.6 years (Range 17-60 years). The mean parity was 5 (Range 1-21). Fifty-four cases reported within 1-2 years time (Range 3 months to 20 years). In Fifty-one cases (72.8 %) delivery took place at home.

Most common site was midvagina 58.57 % (41 cases). Fifty-four cases (91.42 %) were obstetric fistulae caused by prolonged and obstructed labour. Sixty-four cases (91.4 %) were operated vaginally. Success rate was 85.5 % (60 cases).

Vesicovaginal fistula is a common health problem of developing countries caused by obstructed labour. Vaginal approach, utilizing basic surgical principles is simple and easy technique with better results.

KEY WORDS: Vesicovaginal fistula, Obstructed labour, Surgical outcome.

INTRODUCTION

Obstetric complications are as old as human birth. Among the most catastrophic of obstetric complications is the development of a vesicovaginal fistulae from prolonged obstructed labour. In developing countries it occurs in 1-3 / 1000 deliveries ^{1,2}.

The fistulae that do occur in the Europe and the United States today are almost always the result of malignancy, radiation therapy or as a result of complication surgical procedure ³. Across the world, an estimated two million women suffer from this condition. VVF is commonly seen in Africa and Northern Asia. Many factors contribute to this situation. In Africa along with inadequate midwifery services, early marriage, teenage pregnancy and tradition of female circumcision that reduces size of introitus are contributing factors ⁴.

.....
Correspondence:
Dr. Rafia Baloch
Associate Professor,
Department of Gynaecology and Obstetrics,
Chandka Medical College, Larkana

Thompson⁵ has reported that Jhonfatio performed 1st successful repair in 1675 and O' Connor ⁶ cited the work of Sims, father of Gynaecology who performed 1st successful repair in 1849 on a patient who has undergone twenty nine previous failed attempts. The management of vesicovaginal fistulae remains a source of debate despite of extensive literature on the subject.

Recent advancement in surgical technology for repair of traumatic and post irradiation fistulae include Noval technique⁷, transurethral coagulation⁸, fibrin glue⁹, transurethral cystography¹⁰ by new generation needle driver technology, sliding layer method¹¹ and endoscopic ND-YAG laser fulguration¹².

Obstetric fistulae are best managed at center of excellence⁴ by basic rules of fistulae repair viz. good exposure, dissection that allows adequate mobilization and tension free closure and utilization of intraoperative ureteric catheterization and Martius graft in majority of cases.

This study was mainly carried out to know surgical outcome by utilization of basic surgical principles and meticulous postoperative care.

PATIENTS AND METHODS

Shaikh Zayed Women Hospital is a tertiary care 200 bedded Gynaecology & Obstetric unit of Chandka Medical College Hospital, Larkana receiving patients from upper Sindh and part of upper Baluchistan. The total gynae. admissions in five years were 4768. Seventy cases of vesicovaginal fistulae admitted were analysed prospectively from May 1997 to May 2002. The surgery was carried out at least three months after its formation or previous failed attempts at repair. A detailed history was obtained to know sociodemographic features, duration of fistulae, cause of fistulae, previous attempts, duration of labour and associated medical and surgical history etc. Thorough clinical examination was done to assess size, site, vaginal condition and associated rectovaginal fistulae. Preoperative work up included x-ray KUB to exclude urinary calculi. Intravenous urography was done in only two cases of ureteric fistulae. Cystoscopy was done in 37 cases to assess exact size, site and relationship with ureters in large fistulae. Every patient was also examined in theatre in lithotomy position before surgery to assess the surgical approach, its difficulties and associated infection. Patient were given light diet one day prior to operation. Bowel was prepared if associated rectovaginal fistula was present. Patients were reassured and written informed consent was taken. Spinal anaesthesia was given in majority of cases 91.4 % (64) cases. Patient were operated in exaggerated lithotomy position. Prophylactic antibiotics were given. Apart from all instruments for operation additionally ureteric probe, ureteric catheters No. 5 & 6 were arranged for each case.

Awards weighted speculum, Thorek sharply curved scissors and Fischers strong J- shaped needle presence were ensured. In sixty four cases (91.4 %), operations were done vaginally. In six cases (8.6 %) operations were done along with urologist via abdominal approach. Among these six cases, four cases were of high vesicovaginal fistulae and two cases were of ureteric fistulae. Surgical exposure in patients with narrowing of introitus was improved with Schuchardt releasing incisions (which resembles an aggressive mediolateral episiotomy) in three cases. Division of fibrous bands were done in 14 cases. A foley catheter was introduced through fistulous hole and balloon was inflated for traction purpose in some cases.

A circumferential incision was made around the fistulous tract and wide mobilization of flaps was done. The fibrous edges of fistulae were excised. Ureteric catheters were passed in 21 cases having large fistulae. Fistulae were closed in two layers by interrupted inverted sutures with

2/0 vicryl with J shaped needle without penetrating the mucosa of bladder. Vaginal mucosa was closed with 0/0 vicryl interrupted everted sutures transversely. Vaginal packing was done for 24 hours. In majority of cases urethral catheter was kept for two weeks, and ureteric catheter for one week. Antibiotics were continued till catheter was in. Patient was allowed liquid diet with plenty of water to ensure free urinary drainage. Patients were not allowed to move for two weeks till catheter was in. Hygiene and nutritional care was done adequately. Patients were examined in theatre after 2 weeks. If stitch line was alright and dye test negative, then catheter was removed without clamping. In case of little leakage catheter was kept further for 3 to 6 weeks. Patients were advised to pass urine frequently after removal of catheter. Importance of antenatal care and subsequent Caesarean section for next pregnancy was emphasized. Sexual intercourse was avoided for at least three months. In most of cases, surgery was done postmenses, if they start menstruating, menses were stopped by primolut N tablets. Discharge card was issued with full notes and future plan.

RESULTS

The mean age of patients was 34. 6 years (Range 17-60 years) in sixty-four cases (91.42 %) cause was obstructed labour. Duration of labour was more than 72 hours in 60 % (42 cases) Fifty-four cases (77.13%) reported within 1-2 years (Range 3 months to 20 years). Fifty cases (72.8%) were delivered at home. One case was having vesicovaginal fistula since 20 years due to obstructed labour. Two cases were hypertensive, two were diabetics, one with hypothyroidism, two cases had neuropathy and one case was of massive deformities of legs due to postpolio deformity. In past surgical history four had Caesarean hysterectomies, five had gynaecological hysterectomies, one had cystolithotomy, one had renal surgery, one underwent lithotripsy, one case was of RVF repair in past and colostomy done in three cases. Fourteen cases had secondary amenorrhea, five were menopausal, others had normal menses.

Most common site of fistula was midvagina in 41 cases (58.57%). Fifty three fistulae (75.8%) were more than 2cm in size (Range 0.5 to 7 cm). Vaginal scarring was present in eighteen cases (25.71%). In five cases (7.1%) combined vesicovaginal and rectal fistula were present. Along with repair other operations were also done (Table I). In sixty eight cases (97.14 %) it was first attempt, while in one case second attempt and in one case third attempt. Duration of operation ranged from 1-4 hours. Blood loss was about 100-300ml. Blood transfusion was not required in any case. Urethral catheter was retained for 2 weeks in thirty-two (45.71%) cases (Range 2-6 weeks). Better result were obtained in 85.5 % (60 cases) in ten cases of failure, size of fistula was too much

reduced with minimal incontinence. They were called for second attempt but they did not return. In postoperative follow up mild to moderate stress incontinence was also reported. They were advised perineal floor exercises. One case of hypothyroidism developed distension of abdomen and paralytic ileus. She became alright after increasing dose of thyroxine.

TABLE-I ADDITIONAL SURGICAL PROCEDURE

Additional procedure with VVF repair (n=70)	No.
Rectovaginal fistulae repair	5
Cystolithotomy	3
Vaginal hysterectomy	1
Division of dense fibrous vaginal bands	14
Ureteric reimplantation	2

DISCUSSION

In this study, fistula patients were some what older and of high parity than reported from Nigeria¹³, although in most studies it is relatively common in young primiparas^{4,12,14}. In majority of these cases the cause was obstructed labour as reported by other studies from developing countries^{1,2,4,14}. Midvaginal vesicovaginal fistulae were the most common site in our study as reported from other developing countries^{4,14}. However in developed countries common sites were ureteric and vault of vagina³.

Preoperative cystoscopy was done in 37 cases. There was difficulty in doing cystoscopy due to large hole in bladder, and also it did not offer any extra information. Cystoscopy is necessary only in ureteric fistulae. Cystoscopy is needed during major gynaecological surgery for detection of urinary tract injuries and to prevent subsequent fistula formation¹⁶. Preoperative hormones were not used as majority of cases were young. However selected number of patients would benefit from taking oral contraceptive pills in double dose, starting 2 weeks preoperatively and continuing for 2 weeks postoperatively¹⁷. In our series operation was done three months after fistulae formation as recommended by most studies^{4,14}. This allows good blood supply and eradicates infection. However traumatic fistulae can be repaired successfully by early intervention^{18,19}. In our series common route of surgery was vaginal. Usually gynaecologist favour vaginal approach due to its familiarity^{1,2,14} while urologist and general surgeons favour abdominal route^{20,21}. Vaginal route has an added advantage of being easy, direct and avoid abdominal incisions thus reducing postoperative morbidity. Recently anterior sagittal transrectal approach is described in children in sub symphyseal fistula as reported by Domini²². In our series 2 cases were done abdominally due to ureteric fistulae and 4 cases of high vesicovaginal fistulae. Out of four high VVF, only one case showed better results. High failure rate could be due to difficult

fistulae. Although trial of vaginal approach with wide episiotomies might have increased success rate as reported by other studies¹⁴. Regarding surgical technique, controversy exists whether to excise fistulous tract or freshen the edges. In our series fistulous tract edges were excised in all cases as reported by Sims. However Lawson opposes excision of fistulous tissues²³. He favoured freshening fistulous tract without excising it. In our series no graft was used.

A variety of tissues can be interposed between bladder and vagina for closure such as Martius graft of fibrofatty tissues²⁴, gracilis muscle^{24,25}, omentum^{20,26}, free bladder mucosal autograft²⁷, and pedicled flap of vaginal wall as reported by Hurley and Prerite²⁸. In three cases vesical calculus were simultaneously removed. Two cases were cured, one case of high VVF and vesical calculus failed. Although in some studies¹⁷ the removal of stone especially associated with infection followed by VVF repair after 2-3 weeks is recommended. In our series there was small stone without signs of infection. The stone was removed through the fistulous hole. Large stone especially non crushable should be removed abdominally prior to repair¹⁹. In our series VVF and RVF were repaired in the same session as recommended by most studies^{4,17,24,25}.

Preliminary colostomy in RVF patients was done in three cases out of five. Four cases were cured. In one case RVF healed but VVF failed because of large fistula. Antibiotics were continued till catheter was in. However prolong use of antibiotics is again debatable. In some studies the recommendation is to culture urine specimen directly collected from bladder in small fistulae or from ureteric catheter in large fistulae intraoperatively²⁹.

In our series few cases had mild to moderate stress incontinence and were cured conservatively. However more research work is required regarding role of bulbocavernosus graft, on to the abdominal muscles, on to the symphysis pubis or on to the pubococcygeous muscle for prevention of postoperative stress incontinence¹⁷. In our series success was 85.5%. Success was 89.6% in vaginal route and 50% via abdominal route. Success as high as 93 to 96 % is also reported^{4,14,20}. The causes of failure were reviewed carefully. Following were main underlying factors, dense scarring in five cases, urethral stricture in three cases, long duration of fistulae in six cases, previous failed attempt in one case, associated medical disorders, in five cases, combined fistula in one case.

CONCLUSIONS

The vaginal route utilizing good exposure, wide mobilization of tissues, tension free water tight closure of bladder is a simple, easy, safe, effective and more

physiological in majority of cases than other trans abdominal techniques. Meticulous postoperative care and continuous bladder drainage are key to success. However further efforts are needed to improve success rate and also assess effect of Martius graft especially in urethral and midvaginal fistulae as reported from center of excellence⁴.

REFERENCES

- Arrowsmith S, Hamlin, Wall LL. Obstructed labour injury complex: Obstetric fistulae formation and multifaceted morbidity of maternal birth trauma in the developing world. *Obstet Gynecol Surv* 1996; 51: 568-74
- Perveen F, Shah Q. Vesicovaginal fistula: A challenge for women in developing countries. *J Coll Physicians Surg Pak* 1998; 8; 230-2.
- Hilton P. vesicovaginal fistula : New perspectives. *Curr opin Obstet Gynecol* 2001; 13: 513 - 20.
- Kelly J. An epidemiological study of VVF in Addis Ababa. *World Health Stat Q* 1995 ; 48 ; 15 - 7.
- Thompson JD. Vesicovaginal and urethrovaginal fistulas. In; Rock JA Thompson JD (edi). *The Linde's operative surgery*. Vol 28th ed. New york ; L: Lippincott Raven ; 1997 ; 1175 - 1205.
- O' Connor VJ' jr. Review of experience with vesicovaginal fistulae repair. *J Urol*. 1979 ; 123 ; 354 - 69.
- Hsu TH, Ractley RR, Abdelmalak JB, Madjar S, Vasavada SP. Novel technique for combined repair of postirradiation vesicovaginal fistula and augmentation ileocystoplasty. *Urology* 2002; 59: 597 - 9.
- Madjar S, Gousse A. Postirradiation vesicovaginal fistula completely resolved with conservative treatment. *Int Urogynaecol J. Pelvic floor Dysfunct* 2001 ; 12 (6) : 405 - 6.
- Kanaoka Y, Hiraik, Ishiko O, Ogita S. vesicovaginal fistula treated with fibrin glue *Int J. Gynecol Obstet* 2001; 73: 147 - 9.
- Mackay HA. Transurethral suture cystography for repair of vesicovaginal fistulas: evolution of a technique. *Int Urogynecol J Pelvic floor Dysfunction* 2001 ; 12; 282-7.
- Milicic D, Sprem M, Bagovic D. A method for the repair of VVF. *Int J Gynecol Obstet* 2001; 73: 35 - 9.
- Dogra PN, Nabi G. Laser welding of VVF. *Int Urogynecol J Pelvic floor Dysfunct* 2001; 12: 69 -70.
- Hilton P, Ward A, Epidemiological and surgical aspects of urogenital fistulae. A review of 25 years experience in South East Nigeria - *Int. Urogynecol J Pelvic floor Dysfunct* 1998; 9; 189 - 194.
- Sachdev. PS Surgical repair of VVF *J Coll Physicians Surg Pak* 2002. 12: 223 - 226.
- Good no JA, Powers TW, Harris VD. Ureteral injury in gynecological surgery. A ten-year review in a community hospital. *Am J Gynecol* 1996; 172; 1817-20
- G. Imour DT Dwyer PL, Cares MP. Lower urinary tract injury during gynecologic surgery and its detection by intra-operative cystoscopy. *Obstet Gynecol*. 1999; 94 (supp 1): 883-889.
- Kees WSK. Step by step surgery of vesicovaginal fistulas a full colour Atlas 1994. page 20, 92, 99.
- Blandy JP, Badenoch. OF , Fowler CG, Jenkins BJ Thomas NWM. Early repair of iatrogenic injury to the ureter and bladder after gynaecological surgery *J Urol* 1991; 146; 761 - 5.
- Budenoch. DFT: Paff. RC. Thaka. DR, Fowler CG, Blandy JP. Early repair of accidental injury to bladder and ureter. following gynaecological surgery. *Br J Urology* 1987 ; 59 ; 516 - 8.
- Mondet F, Kastler EJ, Conort P, Bitker MO, Chatelian C, Richard F. Anatomic and functional results of transperitoneal transvesical vesicovaginal fistula repair. *Urology* 2001; 58: 882 - 6.
- Evans DH, Madjar S, politano VA, Bajany DE, Lynne CM, Gousse AC. Interposition flaps in transabdominal vesicovaginal fistula repairs, Are they really necessary? *Urology* 2001; 57: 670 - 4.
- Domini: M, Aquin A, Rossi F, et al. Recurrct posttraumatic urethrovaginal fistula a new application for ASTRA. *J. Pediatr. Surg* 2000 ; 35: 522 - 525.
- Lawson JB. Injuries of the urinary tract. In: Lawson JB Stewart DB, (edi) *obstetric and gynaecology in the tropics and developing countries*. London : Edward Arnold 1967; 481 - 522.
- Kelly J. Vesicovaginal and rectovaginal fistulae *J Obstet Gynecol* 1998; 18: 249 - 51.
- Hamlin RHJ, Nicholson EC. Reconstruction of the urethra totally destroyed in labour *Br Med J* 1969; 2; 147 - 50.
- Nabi G, Hemal AK. Laparoscopic repair of vesicovaginal fistula and right nephrectomy for non functioning kidney in a single session. *J Endourol* 2001; 15: 249 - 51.
- Sharifi AF, Ghaderian N, Payvand, A. Free bladder mucosal autograft in the treatment of complicated vesicovaginal fistula. *Br J Urol Int*. 2002, 89 suppl 1: 54 - 56.
- Hurley. LJ. Prente SR. Vaginal pedicle flap for closure of vesicovaginal fistula. *Urology* 2002; 56; 856.
- Tomlinson JA : A Randomised controlled trial of antibiotic prophylaxis for VVF repair. *Br J Obstet Gynaecol* 1998. 105 397 - 399.
- Report on the meeting for the prevention and treatment of obstetric fistula - London June 2001.
- Hamlin E.C. Muleta M. and Kennedy. R.C. Providing an obstetric fistula service *Br J Urol Int*. 2000, 89. Supp. 50-53.



CORRELATION OF CT SCAN AND HISTOPATHOLOGY IN BRAIN TUMOURS

MALIK MUHAMMAD KHALID

ABSTRACT:

The objective of this study was to determine the preoperative diagnostic accuracy of CT Scan in brain tumours and compare it with post-operative histopathology results. This study was conducted at PNS Shifa Naval Hospital Karachi over a period of four years from December 1995 to December 1999. A total of 100 patients were included who underwent computed tomography (CT) scan for suspected brain tumours. Selection criteria included those single intracranial masses labeled as brain tumour on the basis of their CT features. Multiple lesions were excluded. The patients' age ranged from 13-85 years, mean age 43 years with male to female ratio 2:1. The common clinical presentations were headache, diplopia, seizures, personality changes, vertigo, vomiting and progressive neurological deficit. The results of our study revealed that out of hundred cases gliomas were 48, meningiomas 25, pituitary adenomas 12, craniopharyngiomas 6, pineal region tumours 4, acoustic neuromas 3 and choroid plexus papilloma 2. The diagnostic accuracy of CT scan was found to be 83% on average, when correlated with histopathology.

KEY WORDS: Brain tumours, CT scan, Histopathology

INTRODUCTION

The advancement in neuroimaging brought about by computed tomography (CT) scan is considered by some as the greatest step forward in the century old history of radiology, after the discovery of x-rays by Roentgen in 1895^{1,2,3}. Before the advent of CT in 1972, reliable and accurate confirmation of presence or absence of brain tumours involved use of invasive diagnostic procedures, such as pneumoencephalography, cerebral angiography and various other studies. All these techniques carried considerable degree of morbidity and mortality^{3,5,6}. CT has replaced these invasive studies because it can accurately demonstrate, localize and characterize brain tumours^{2,5,7}. Earlier diagnoses have been made possible with CT because of greater sensitivity and specificity^{8,9}. This study has been carried out to define the role of CT in our setup and to assess its diagnostic accuracy in brain tumours preoperatively. Emphasis was laid on the CT appearances of various brain tumours before surgery or biopsy and their follow up till histopathological confirmation was reached.

.....
Correspondence:

Dr. Malik Muhammad Khalid
Radiology Department
Combined Military Hospital
Multan Cantt.

MATERIAL AND METHODS

This was a hospital based study carried out in the Radiology Department of PNS Shifa Naval Hospital Karachi over a period of four years (December 1995 to December 1999). Only those patients were included in the study who fulfilled the laid down criteria. The patients excluded from the study were:

1. Where multiple lesions were noted on CT, suggestive of metastases or granulomas.
2. Where postoperative histopathology report was not available.
3. Patients who refused surgery and those who were lost to follow up.
4. Children under the age of 12 years.

We selected 100 cases of various brain tumours, who underwent CT in our department during four years. Patients belonged to both sexes (M:F, 2:1) and their age ranged from 13-85 years, with mean age of 43 years (table I)

The CT scan machine in our department was Hitachi x-ray CT system W-1000. This system combined a rotatory fan beam source and 668 stationary detectors. It had 1000 mA tube head. Available scan times were 1.2 to 7.6

seconds. Image reconstruction time was 2.8 seconds. Slice thickness obtained by this system was from 1.5 to 10 mm. Axial and coronal scan could be done directly. Sagittal reconstructions were made whenever required. The gantry had diameter of 75cm, with tilting angle of 25 degrees on either side. Image matrix was 320 and 512 with 3-D image reconstruction capability.^{10,11} Image storage was done on magnetic tape and on the hard disc of the computer system. CT image was obtained on x-ray films with multiformat camera. A record of the positive cases was kept on the floppies.

Before commencement of CT examination the patient was registered. Brief clinical history was taken to ascertain the presenting complaints, their duration, physical signs and notes by the referring clinician. Any previous surgery or interventional procedures were noted. Investigations like X-ray skull, ultrasound, radioisotope scan, previous CT scan, MRI, where available, were correlated.

The patient was explained the procedure of CT in simple words. Any history of allergy was recorded and element of risk was told in cases of contrast use. The patient was confirmed to be empty stomach. Any hair pins and other metallic structures were removed from the head to avoid streak artifacts. Patients were also requested to remain still during the procedure to avoid motion artifacts.

RESULTS

The results obtained in our study on the basis of CT features were following:

1. Gliomas were by far the commonest tumours in our study (48%). Histopathologically gliomas are graded I-IV depending on mitotic figures^{7,17}. CT scan determine the degree of malignancy on the basis of tumour size, necrosis, calcification, oedema, haemorrhage and contrast enhancement^{7, 8, 13, 18}.

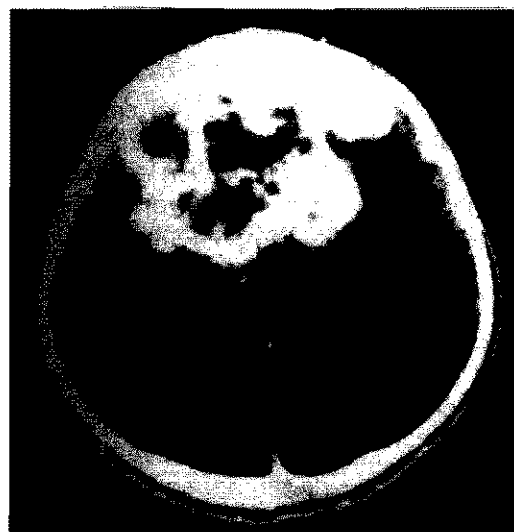


Figure 1: Glioblastoma multiforme in a 59 year old male showing a hypodense frontal mass with irregular enhancement after i.v. contrast, central necrosis and marked peritumoral oedema.

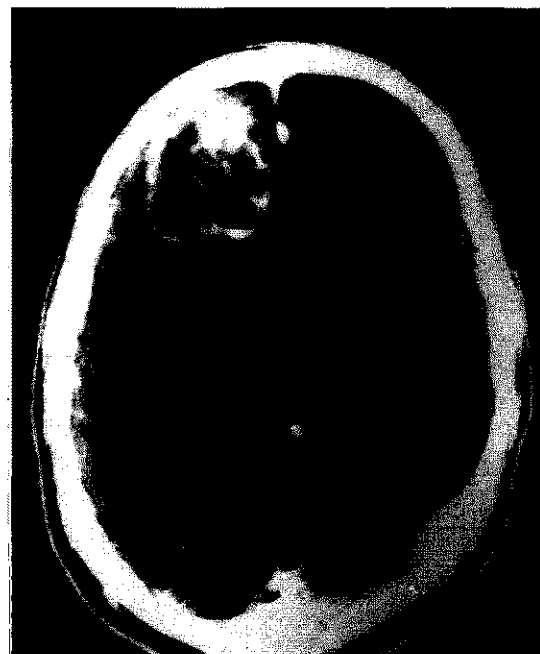


Figure 2: Glioblastoma multiforme in 64-years-old female showing a hypodense parieto-occipital mass, irregular ring enhancement after iv contrast, central necrosis and peritumoral oedema.

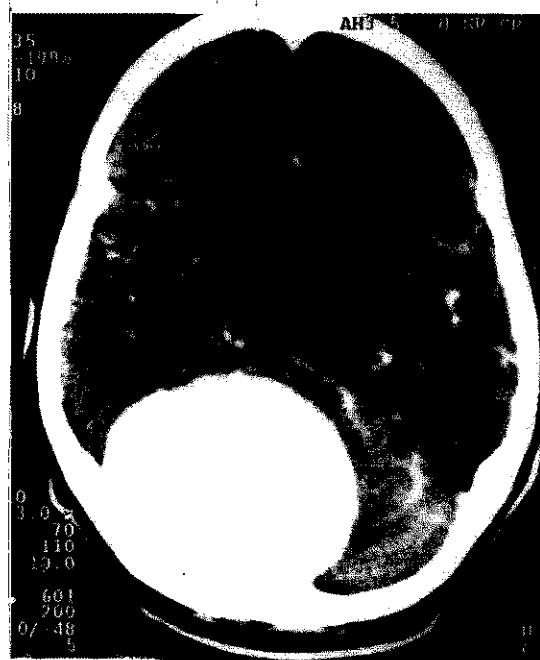


Figure 3: Occipital meningioma in 55 years old female showing large well defined densely enhancing mass with ventricular dilatation.

On the basis of CT features 19 patients were placed in low grade (I & II) and 29 patients in high grade malignancy (III & IV),(Figure 1 & 2).

2. Meningiomas are the intracranial extracerebral supratentorial tumours that tend to arise at characteristic sites (Figure 3 & 4). Typical CT appearance facilitates correct diagnosis and curative treatment in most of the cases^{18, 19}. 25% of our patients fell in this category. Calcification was found in half of them and all were enhancing with contrast^{9, 19}. Oedema was noted only in 4 cases.
3. Pituitary adenomas (12%) presented as rounded

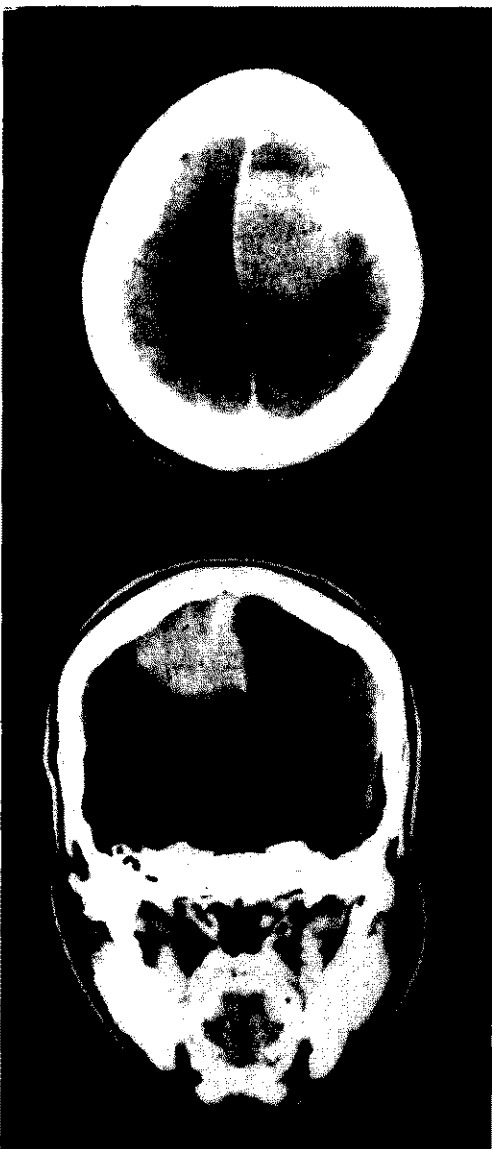

Figure 4: Parasagittal meningioma in 42-years old female. Coronal and axial contrast-enhanced CT images, showing well-defined uniformly enhancing mass.

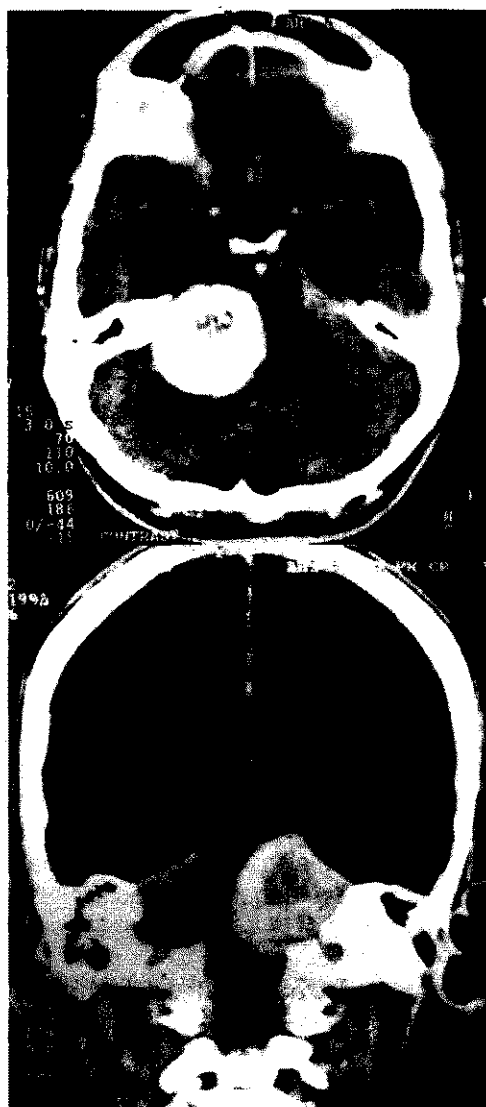


Figure 6: Acoustic neuromas in a 45-years old female. Contrast enhanced axial and coronal scans showing densely enhancing cerebellopontine angle mass and mild hydrocephalus.

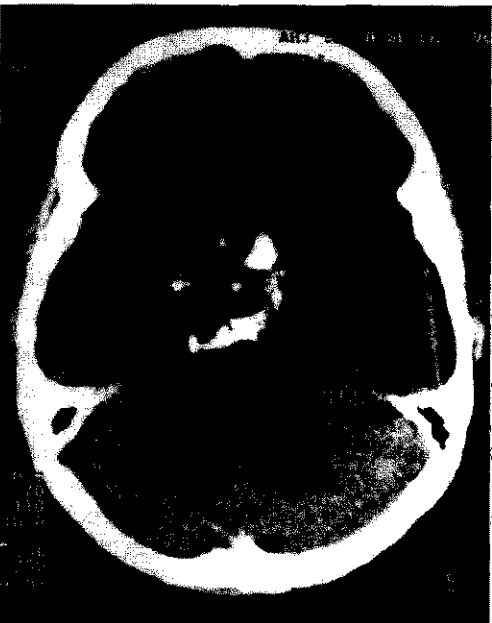


Figure 5: Craniopharyngioma in 28-years old male. Non-enhanced axial scan showing a low density area with dense globular calcification in suprasellar region.

intra/suprasellar masses slightly denser than brain, showing homogenous contrast enhancement ²⁰.

4. Craniopharyngioma (6%) presented as rounded midline suprasellar mass with low central attenuation and partly calcified capsule ^{3, 20}, (Figure 5).
5. Pineal region tumours 'Pinealomas' (4%) cannot be further differentiated into histological types on the basis of CT features ^{21, 22}. Their location adjacent to often calcified pineal gland results in hydrocephalus. The tumour enhances markedly with contrast, bulges anteriorly into third ventricle, hence easily diagnosed on CT.
6. Acoustic neuromas (3%) are commonest extracerebral tumour located in cerebellopontine angle (Fig 6). They are diagnosed on CT when already large in size; smaller lesion can only be picked on CT cisternography ²³.

7. Choroid plexus papilloma (2%) are intraventricular masses often presenting with hydrocephalus, occasionally calcified, show marked contrast enhancement²⁴.

TABLE-I AGE DISTRIBUTION

Age group	Number of patients (100)
13-30 years	25
31-50 years	35
51-70 years	28
71-85 years	12

TABLE-II CLINICAL PRESENTATIONS

Symptoms	Percentage of patients
Headache	76
Diplopia	30
Seizures	84
Visual Defect	44
Personality change	36
Hemiparesis	22
Vertigo	26
Vomiting	62
Papilledema	40

HISTOPATHOLOGICAL CORRELATION

The aim of this study was to characterize the brain tumours, pre-operatively, on the basis of their CT features. Although this is not always possible, still CT can predict the pathological nature of a lesion with reasonable degree of accuracy^{8,9}. Out of our 100 selected cases histopathological correlation was available in all as 88 patients were operated upon and biopsy was obtained in the remaining 12, who were inoperable.

In 48 cases of suspected gliomas, 19 were labeled as of low-grade malignancy on CT. Histopathology report showed that 8 were in grade I (astrocytoma), 3 in grade II (oligodendroglioma), 7 in grade III (glioblastoma) and one turned out to be primary brain lymphoma (microglioma). Out of 29 cases showing high-grade malignancy (grade III/IV) on CT, 22 correlated well on histopathology. Five cases were found to be solitary metastatic deposits from unsuspected primary carcinoma bronchus. Two cases of low-grade glioma on CT were diagnosed as tuberculomas on histopathology thus completely altering their prognosis. CT and histopathology diagnoses were in agreement in all cases of meningiomas, pituitary adenomas and acoustic neuromas.

One case of craniopharyngioma out of six was found to be a chordoma on histopathology. In case of pineal region tumours various histological types could not be differentiated on the basis of CT appearance. Out of the two cases labeled on CT as choroids plexus papilloma,

one was found to be ependymoma on histopathology. During the post-operative follow up CT scan was done in twenty three patients, out of which four cases showed recurrence of glioblastoma.

DISCUSSION

Brain tumours are not uncommon in our setup. Symptoms are usually subtle but high degree of clinical suspicion and availability of CT has resulted in more frequent diagnosis at an early stage. Before the advent of CT the diagnosis of brain tumour was not possible by non-invasive means^{1,2}. These features occur due to increased intracranial pressure from mass effect of tumour and/or peritumoral edema^{3,4,13,14}. These features are typical of supratentorial locations. Blockage of CSF drainage (hydrocephalus) was less common in supratentorial tumours. Seizures occur from irritation and damage of cerebral cortex by the tumour mass^{15,16}. A study conducted by National Survey of Care for Brain Tumour Patients in USA² revealed that the most common clinical presentations of brain tumour were a progressive neurological deficit (68%), usually motor weakness (45%), headache (54%) and seizures (26%). These clinical manifestations only slightly differed from our study, the reason being less number of patients and different purpose of our study.

CT has become the primary imaging investigation in cases of suspected brain tumours, surpassing many other invasive imaging modalities of the past^{4,5,6}. A general awareness was noted in the patients regarding the benefits of CT despite high cost and less availability in our country. Plain X-ray skull is no more advised in such cases being of little value^{9,12}. In our study only 32 patients had an X-ray skull done, out of which only two were positive. One showed enlarged sella with erosion of lamina dura and the other revealed calcification in convexity meningioma. Nuclear scan was done only in one case showing a space-occupying lesion in one hemisphere. Though MR imaging is available these days but it is expensive and is usually done once CT scan is negative and there is strong clinical suspicion of brain tumour. Seventeen of our patients had MRI scan done which demonstrated the same findings as already picked on CT. MRI has a disadvantage of not showing calcification and recent hemorrhage^{7,11,19}.

The relative incidence of brain tumours in our study closely resembled a study conducted in USA and mentioned in the Osborn's Diagnostic Neuroimaging². According to this study the primary brain tumours accounted for more than two thirds of all brain tumours (gliomas 45%, meningiomas 23%, others 11%), and metastases were 21%. We excluded metastases from our study, as these patients are usually not operated, though these were diagnosed on CT in 42 cases during four years of our study. The results of this study closely resembled

our study.

CONCLUSIONS

The diagnostic accuracy of CT scan in our study was found to be 83% on average (range 68% to 100%). Accurate histological grading of the gliomas on CT was not always possible when compared to histopathology; hence an accuracy of 68% was noted in this respect. However a 100% CT accuracy was noted in cases of meningiomas, acoustic neuromas and pituitary tumours. Computed tomography is the primary non-invasive imaging modality for the evaluation of brain tumours. It is unusual to fail to detect the tumour at the time of clinical presentation when a satisfactory study has been performed^{1, 15, 16}. CT has proved to be very effective in the demonstration of intracranial neoplasms. Under most circumstances, CT appearances can suggest a morphological diagnosis with high degree of accuracy. CT is more sensitive in picking calcification and hemorrhage^{7, 9, 19}. In our country where MRI facility is limited, CT will continue to play a significant role in allowing not only preoperative correct diagnosis, but also detection of recurrence of tumours. CT can also help in determining the effectiveness of type of therapy^{2, 14}. Many interventional procedures like biopsies and aspirations can also be done under CT guidance. Thus CT has established its place as primary non-invasive imaging modality in management of patients with brain tumours.

REFERENCES

1. Raymond DA, Fred H, Henry FW, Neoplastic Diseases of Brain in Harrison's Principles of Internal Medicine, ed 9, McGraw Hill Book Company. London, 1993: 1915-1960.
2. Burger PC, Scheithauer BW, Vogel FS: Surgical Pathology of the Nervous System, ed 3, a Comprehensive Textbook, pp. 193-405, New York: Churchill Livingstone, 1991.
3. Mahaley MS, Mettlin C, Natarajan N, et al: National Survey of Pattern of Care for Brain Tumor Patients. J Neurosurg. 1989 71: 826-36.
4. Kreschmann HJ, Weinrich W: Cranial Neuroimaging and Clinical Neuroanatomy- MRI and CT, Thieme Medical Publishers. New York, 1992: 86-113.
5. Zimmerman RA, Rao KCV, Lee SH, Cranial MRI and CT, ed 3, Mc Graw-Hill, Inc, New York, Toronto, 1992:1-39 and 295-441.
6. Jelenik J, Smirniotopoulos JG, Kanzer M: Lateral ventricular neoplasms of the brain: differential diagnosis based on clinical, CT, and MR findings, AJNR 1990 11:567-574.
7. Lavaroni A, Leonard M: Neuroradiological diagnosis of brain tumours in adults, Neuroradiol (suppl 2): 1993: 41-54.
8. Curry ST, Dowdey EJ, Murry RC, ed 4, Christensen's Physics of Diagnostic Radiology, Lea and Febige, London, Philadelphia, 1990,289-322.
9. Mathew F. Clinical Imaging,, Introduction to role of imaging in clinical practice, Churchill Livingstone, London, New York, Melbourne, 1988, 551-558.
10. Russell DS, Rubinstein LJ: Pathology of Tumors of the Nervous System, ed 5, Baltimore, Williams and Wilkins, 1989.
11. Osborn AG, Textbook of Diagnostic Neuroradiology , Philadelphia, 1995, 401-670.
12. Packer RJ: Clinical presentation of brain tumors, Categorical Course: Neoplasms of the Central Nervous System, pp 23-27, American society of Neuroradiology, 1990.
13. Williams A.A, Haughton VM, Cranial Computed Tomography, A Comprehensive Text, The CV Mosby Company, Tronto, Princeton, 1985, 148-239.
14. Pettersson H, A Global Textbook of Radiology, The NICER Centennial Book, Vol-1, 167-228, 1995.
15. Castillo M, Scatliff JH, Bouldin TW, Sowki K: RadiologicO pathologic correlation: intracranial astrocytoma, AJNR 1992 13:1609-1616.
16. Atlas SW: Adult Supratentorial Tumors, Sem Roentgenol 1990 25:130-154,
17. Vertosick FT Jr, Selker RG, Arena VC: Survival of patient with well-differentiated astrocytomas diagnosed in the era of computed tomography, Neurosurg 1991 28:496-501.
18. Hershey BL: Suprasellar masses: diagnosis and differential diagnosis, Sem US, CT, MR 1993 14:215-213.
19. Naidich TP: Imaging evaluation of meningiomas, Categorical Course on Neoplasms of the Central Nervous System, American Society of Neuroradiology, 1990 39-51.
20. Kleihues P. Burger PC, Scheithauer BW: The new WHO classification of brain tumors, Brain Pathology 1993 3:255-268.
21. Sheporaitis L, Osborn AG, Clunic DA: Radiologic-Pathologic Correlation intracranial meningioma, AJNR 1992 13:29-37.
22. Buetow MP, Burton PC, Typical features in meningioma, Radio Graphics 1991 11:1087-1100.
23. Lo WM: Cerebellopontine angle tumors, Categorical Course on Neoplasms of the Central Nervous System, American Society of Neuroradiology, 1990 72-75.
24. Sutton D, Ivan M, Textbook of Radiology and Imaging Vol 2, ed 5, Churchill Livingstone, London, New York, Tokyo, 1993, 1499-1536.



BASAL CELL CARCINOMA

HAFEEZULLAH ABRO, ATTA HUSSAIN SOOMRO,

SIRAJ ABBASI, QAMAR BALOCH

ABSTRACT:

The objective of the study is to document results of various modes of treatment in cases of basal cell carcinoma. This is a five-year retrospective study conducted between January 1994 and December 1998 at Chandka Medical College & Larkana Institute of Nuclear Medicine and Radiotherapy (LINAR).

The cases were collected from surgical wards and Larkana Institute of Nuclear Medicine & Radiotherapy, where cases were referred from Dermatology OPD directly. The total number of patients under study were 46. Surgery was done in 12 cases (26%) & Radiotherapy in 23 cases (50%), in remaining 11 cases (24.0%) combination of surgery, radiotherapy & chemotherapy were given when one mode of treatment failed. The youngest patient was of 30 years, while the eldest was of 90 years. The male to female ratio was 1:1. The majority of patients were field workers. In surgery group only one recurrence out of 12 cases (8.33%) occurred, while in radiotherapy group 11 recurrences occurred out of 23 (47.82%) cases. In our study, surgery had better results than radiotherapy.

KEY WORDS: Basal cell carcinoma, Surgery, Radiotherapy.

INTRODUCTION

Basal cell carcinoma (BCC) is the commonest skin malignancy in the body. Skin is one of the most sensitive organs of the body and is constantly exposed to sunlight.¹ The sunlight emits various types of radiations. These radiations have harmful effects on the skin. The solar radiation is blamed for the development of basal cell carcinoma². Since this tumour is locally malignant, and also slow growing, its mortality is negligible but morbidity and burden on health services is an important issue in UK³. Basal cell carcinoma most commonly involves the upper part of the face. The four main types are noted. These are nodular, ulcerative, pigmented morpheaform & superficial. Actinic keratosis is said to be premalignant condition, hence basal cell carcinoma can be prevented if we can prevent the development of actinic keratosis by regularly using sunscreen⁴. Tissue biopsy is the mainstay for establishing histopathological diagnosis before offering the treatment. Surgery alongwith or without radiotherapy are the main modalities of the treatment, depending upon the tumour size, site and the willingness

of the patient. This study was done to get on audit the result of BCC.

PATIENTS AND METHODS

Forty-six patients of BCC were selected from outpatient departments of surgery and LINAR. Dermatology OPD was the main referring source to LINAR. Patients from surgical OPD, were admitted in the ward for tissue diagnosis, while patients from dermatology OPD were directly referred to LINAR, where punch biopsy was done in each case before any treatment was offered. Third group of patients were non-responders to radiotherapy and received combination of chemotherapy and or surgery.

RESULTS

Over a period of five years from January 1994 to December 1998, forty six cases were collected. The mean age was 54.67 years \pm 11.89, ranging from 30 to 90 years (Table I). The male to female ratio was equal. Forty two patients had nodular/ulcerative lesion over the upper part of the face close to the nose (Table II). The duration of symptoms varied from 4 months to 15 years. The size of lesion ranged from 0.3 to 5.0 cm. The majority of cases were farmers (n-39-85%).

.....
Correspondence:

Dr. Hafeezullah Abro

Chandka Medical College and

Larkana Institute of Nuclear Medicine and Radiotherapy

Larkana.

TABLE-I AGE DISTRIBUTION

Age in Years	No of Patients	Percentage
30 – 50	16	34.78
51 – 70	27	58.69
71 – 90	3	6.52

TABLE-II LOCATION OF TUMOUR

Site	Number	Percentage
Face	42	91.30
Shoulder	1	2.17
Scalp	1	2.17
Scrotum	1	2.17
Groin	1	2.17

TABLE-III TREATMENT & RECURRENCE RATE

Treatment	No. of Cases	Recurrences	Percentage	95% C.I. *
Surgery only	12	1	8.3	30.0—34.74
Radiotherapy only	23	11	47.82	28.29—67.78
*Combine therapy	11	5	45.45	18.96—74.07

Chi- square=5.73, P< 0.06

* C.I = Confidence Interval.

**Combine therapy = Nonresponders of Radiotherapy who were offered Surgery/Chemotherapy.

DISCUSSION

Skin is one of the most sensitive organs of the body and is constantly exposed to sunlight. When this exposure continues for longer period as evident in field workers, it may develop certain skin changes, which may lead to development of basal cell carcinoma usually on the face, as reported by many researchers^{1,2,6,7}. The way by which these changes lead to the development of BCC is not well understood but the mutation in the p53 gene is seen in BCC due to prolong exposure to sun light^{5,10}. The BCC is the commonest malignant skin tumour as indicated in various studies^{9,11,13,14} and the same was observed in our study as well.

BCC is prevalent at the age of >50 years as observed in the study of Lear-JT³ and similar findings were observed in our study. Previously it was observed and mentioned that BCC is common among white skin population^{3,13}, while in our study and study carried out in Qatar, differs in this regard. BCC in coloured population is as common as in white population¹¹.

In most of the studies, BCC is predominantly seen in male population³, but in our study males and females are equally affected (1:1 ratio). An Irish study also showed the similar results⁶. The increase number of female affectees is due to equal exposure to sunlight while working together with male partners in the field.

The main modalities of treatment are surgery and radiotherapy³. Face lesions less than 4 c.m are best-treated surgically⁶. The kind of surgery that can be preferred is surgical excision with tumour free margin of atleast 0.5 c.m, confirmed on frozen section and followed by immediate plastic reconstruction to have best cosmetic results¹².

Patients seen in dermatology outpatient department were directly referred to radiotherapy department (LINAR), where punch biopsy & histopathology was done and then radiotherapy was instituted. Those patients who were seen in surgical outpatient department were admitted in the ward & treated surgically by excision biopsy followed by plastic reconstructive surgery simultaneously. The reported recurrence rate in radiotherapy group is 7.5% and in surgical group 0.7%¹⁰, while in our study the recurrence was 8.33% in surgery group, 47.82% in radiotherapy group and 45.45% in combination therapy group.

It is difficult to assess the true recurrence rate as it was not a controlled study and follow up was also incomplete. Prevention of BCC among field workers (farmers) has been stressed. Regular use of sunscreen during fieldwork reduces the cutaneous neoplasia by suppressing the precancerous lesions⁴. It is suggested that screening program in the sensitive population, be carried out regularly and biopsy from suspicious lesion of skin is also advised for early detection and treatment¹³.

REFERENCES

1. Maia M; Proenca NG, de-Moraes JC Risk factors for basal cell carcinoma-case control study. *Rev Saud-Publica*-1995; 29: 27-37
2. Rosso s; Zanetti R; Martinez C; Laurent R, Schrameeck C; Talamini R, Tumino R, Wechsler J. The multicenter south European study 'Helios'. II Different sun exposure patterns in the etiology of BCC & Sq: Cell carcinoma of the skin'. *Br J Cancer*.1996 ;73:1447-54.
3. Lear JT, Smith AG. Basal Cell Carcinoma . *Postgrad Med J*.1997 73:538 – 42 .
4. Nayler MF, Boyd A, Smith DW, Cameron GS, Hubbard D, Neldner KH . High sun protection factor, sunscreen in the suppression of actinic neoplasia. *Arch-Dermatol*. 1995 ; 131: 170 - 5
5. Matsumara-Y ; Nishigori-C ; Yagi -T ; Imamura-S ; Takebe-H . 'characterization of p53 gene mutation in BCC. Comparison between sun exposed and less exposed skin area '. *Int - J -Cancer* 1996 15; 65 : 778 – 80.
6. English DR, Armstrong BK, Kricke A, Fleming. Sunlight & Cancer. *Cancer Causes Control* . 1997 ; 8: 271 – 83 .
7. Gutierrez S C, Wrone S T, Sun X, Krueger JG, Coven T, Nickoloff BJ. Sunlight induced BCC tumour cells & Ultraviolet B irradiated psoriatic plaques express Fas Ligand (CD 95 L). *J Clinic Invest* . 1998 ; 101: 33 –9.

8. Healy E, Collins P, Barnes L. Nonmelanoma skin cancer in an Irish population –An appraisal of risk factors. *Ir Med J*. 1995 ; 88 : 58 – 9
9. Avril MF, Auperin A , Marguitin A , Gerbault A , Duvillard P , Benhamou E , Basal Cell Carcinoma of face .Surgery or Radiotherapy ? Results of randomized study. *Br J Cancer* . 1997 ; 76 : 100 – 6 .
10. D'Errico M , Calcagnile AS , Corona R , Fucy M , Annessi G , Baliva G , Tosti ME , Pasquini P , Dogliotti E . p 53 mutation and chromosome instability in BCC developed at an early or late age. *Cancer Res* . 1997 ; 57 : 747 – 52.
11. Mahmoud SF, Azadeh B. ' Basal Cell Carcinoma in Qatar ' . *Int J Dermatol* .1996 ; 35 704 – 6.
12. Holbach LM , Junemann A , Muhammad S . Surgical treatment of periocular BCC using frozen section control & immediate Plastic reconstruction – Indications & methods in 106 patients .*Klin Monatsbl Augenheilkd* . 1998 ; 213 : 278 – 83 .
13. Marghoob AA .Basal Cell Carcinoma . What every primary care physician should know ? *Postgrad Med J* . 1997 ; 102 139 – 42
14. Siddiqui NA. Pattern of skin cancer at tertiary referral hospital in Karachi . *J Coll Physicians Surg Pak*.1998 ; 8 : 56 – 59 .



TOPICAL APPLICATION OF GLYCERYL TRINITRATE 0.2% FOR FISSURE-IN-ANO

MAHMOOD YOUSUF, MUDABBIR HUSSAIN, HUMAIRA JAMAL YOUSUF

ABSTRACT:

This study was carried out from January 2002 to August 2002 to evaluate the efficacy of glyceryl trinitrate (GTN) 0.2 % in healing of fissure-in-ano Sixteen consecutive patients were recruited with proven fissure in ano of more than 6 week duration. Treatment with topical GTN 0.2% was instituted. Patients were assessed at 1, 3, 6, 12 and 26 weeks. Resolution of symptoms, time taken to heal and occurrence of side effects were recorded. Success rate was 79% at 12 weeks, reduced to 64% at 26 weeks. Two patients had recurrence of fissure; one was successfully treated with a further treatment with topical GTN while the other opted for lateral internal sphincterotomy.

KEY WORDS: *Chronic anal fissure, Glyceryl trinitrate, Lateral internal sphincterotomy.*

INTRODUCTION

Anal fissure is a painful longitudinal or elliptical ulcer in the anoderm, extending from below the dentate line to the anal verge. Chronic fissure is associated with significant fibrosis, hypertrophied papillae and a sentinel pile. Treatment of anal fissure has been based on the principle of sphincter relaxation, which reduces spasm, increases blood supply, breaks the vicious circle of pain, spasm and ischaemia and allows healing to take place. Until recently this sphincter relaxation has been interventional, either in the form of manual dilatation or lateral sphincterotomy. Both these methods, though effective, carry a small but definite risk of incontinence. The incidence of incontinence varies, but has been reported to be of the magnitude of as much as 30%^{1,2,3}

More recently the same principle of sphincter relaxation has been tried by pharmacological agents. The term "chemical sphincterotomy" has been coined in the last decade which now encompasses treatment with nitric oxide (NO) donors, eg. Glyceryl trinitrate (GTN), isosorbide dinitrate (ID), calcium channel blockers like nifedipine and diltiazem and more recently botulinum toxin^{4,5,6,7}. NO donors also produce vasodilatation of local blood vessels as well as reduce intra-anal pressure and

hence may further assist healing.

We describe our experience of treating patients with fissure in ano with local application of GTN 0.2% ointment.

PATIENTS AND METHODS

Sixteen consecutive patients with diagnosis of anal fissure and symptoms of six weeks duration were included. Patients who were already on oral nitrates or calcium channel blockers were excluded. History of previous anal surgery did not constitute an exclusion criterion. Detailed history of symptoms and co-morbid conditions was recorded. Diagnosis of fissure was made by the history of anal pain and visual confirmation of fissure by parting the buttocks. Further examination of the anal canal by digital rectal examination and proctosigmoidoscopy was carried out where tolerated by the patient at first consultation or at a later stage during the course of treatment. Age and sex of the patient, duration of symptoms, previous surgery and recent childbirth were recorded. The site of fissure was noted and the findings on digital rectal, proctoscopic and sigmoidoscopic examinations were recorded. Symptom relief and side effects were noted at each visit and evidence of healing was recorded after sixth week onwards.

The details about the course of treatment was explained to the patients. The method of application of GTN 0.2 %

.....
Correspondence:

Dr. Mahmood Yousuf
Associate Professor of Surgery
Hamdard University Hospital
Karachi.

was explained, i.e. a pea sized ointment applied at the anal verge with a gloved finger twice a day. Patients were advised not to apply the ointment intra-anally and to continue treatment for a six week period irrespective of whether the fissure had healed or not. If the symptoms persisted at 6 weeks, a further course of 2 weeks was given. Patients were warned about the main side effect i.e. headache.

Patients were followed up in the out patient clinics at^{1, 3, 6, 12} and 26 weeks or at any other time if they experienced severe headache. The results were analysed in terms of alleviation of symptoms and healing of fissure and any recurrence.

Patients who could not tolerate the treatment and those who failed to respond after three months were offered lateral internal sphincterotomy. Patients who had recurrence of fissure were given the choice of re-commencing a further course of GTN treatment or lateral internal sphincterotomy.

RESULTS

Two patients (one male and one female) did not return after the initial consultation and were excluded from the analysis. There were 9 male and 5 female patients, age 17 to 55 years (mean 33.2). Duration of symptoms varied from 6 to 52 weeks (mean 16). Ten patients had history of constipation while 2 had recent diarrhoea. All patients experienced pain on defaecation and 7 had history of bleeding per rectum. Twelve patients had posterior midline fissures and 2 had anterior. These two females were among 3 who had history of recent childbirth. Two patients had previous history of haemorrhoidectomy while 1 had anal dilatation in the past. All 14 patients completed 12 week follow up while 11 patients completed 26 week follow up. Response to treatment is shown in Table I.

	Resolution	Partial response	No response	Recurrence
1 week	4	3	7	-
3 weeks	9	2	3	-
6 weeks	11	1	2	-
12 weeks	11	1	2	-
26 weeks*	7	-	2	2

Of the two patients who had recurrence of symptoms, one opted for sphincterotomy and one re-commenced treatment with GTN. All the three post partum patients had complete resolution of symptoms at 3 weeks and remained symptom free at 26-week follow-up.

Eleven patients had headaches; this was mild in 6 and had resolved in all except one at the end of one week. Five patients experienced severe headache initially; in 3 of these this subsided after 1 week. One patient

requested sphincterotomy on account of headache and one patient who had persistent headache at 3 week follow up refused further treatment. At the end of the study only two patients underwent lateral sphincterotomy, one on account of recurrence and the other because of intolerable headache and so far both remain symptom free and without recurrence.

DISCUSSION

The role of "chemical sphincterotomy" is finding a definite place in the management of fissure in ano. We obtained quite good results resolution of symptoms and healing of fissure, in line with those reported by other authors. Jonathan Lund reported success rate of 68%⁸ while Ward Dl et al quote success rate of 75%⁹. We feel that particularly in our environment, where patients are worried about surgery and often refuse surgical treatment, this should be offered as a first line treatment.

Anal fissure is a puzzling condition. The actual cause of anal fissure, the reasons for its failure to heal, its predilection for posterior midline position and the paucity of granulation tissue are perplexing features. Hard stools causing initial trauma may be the initiating event. The reduced blood supply in the posterior midline is probably the reason for the formation of an ulcer at this site. Post-mortem studies have shown reduced number of branches of inferior rectal arteries and diminished capillary density in the posterior commisure¹⁰. Anodermal blood flow has been shown to increase after lateral internal sphincterotomy and topical application of nitrates^{11,12}. The good prognosis in post-puerperal cases and relatively poor prognosis in patients who have had a haemorrhoidectomy may also be related to local blood supply. One of our recurrences occurred in a patient with extensive post-haemorrhoidectomy scarring.

Sphincter spasm seems to be a key factor in the non-healing of fissure. Relaxation of the sphincter results in healing despite the lack of granulation tissue. Nevertheless the additional advantage of GTN in local vascularization by means of NO donation probably makes this the treatment of choice because calcium channel blockers simply relax the spasm and botulinium paralyzes the muscle and may therefore be associated with later leaks. This may the reason for our very good results, as has been found by others. Our second late recurrence was associated with constipation. Perhaps continued attention to this factor should be instituted as part of the overall management. Two patients discontinued treatment because of headache. This is important because healing takes several weeks. Reduction of dose in these sensitive patients is a plausible strategy. In addition, the effect on revascularization and healing by smoking needs consideration.

In conclusion, we have shown that non-operative treatment of chronic anal fissure by means of GTN results in a high cure rate with a marked reduction of surgery in patients with anal fissures and is probably the initial treatment of choice in our circumstances.

REFERENCES

1. Abcarian H. Surgical correction of chronic anal fissure: results of lateral internal sphincterotomy versus fissurectomy-midline sphincterotomy. *Dis Colon Rectum* 1980; 23: 31-36
2. Milito G, Arullani A, Brancalone C, Cesca D, Filingeri V, Casciani CU. Subcutaneous lateral internal sphincterotomy in the treatment of chronic anal fissure. *Italian J Surg Sci* 1983; 13: 275-79
3. Khubchandani IT, Reed JF. Sequelae of internal sphincterotomy for chronic fissure in ano. *Br J Surg* 1989; 76: 431-34
4. Cook TA, Humphreys MM, Phillips RK. Oral nifedipine reduces resting anal pressure and heals chronic anal fissure. *Br J Surg* 1999; 86: 1269-73
5. Knight JS, Birks M, Farouk R. Topical diltiazem ointment in the treatment of chronic anal fissure. *Br J Surg* 2001; 88:553-56
6. Jost WH. One hundred cases of anal fissure treated with botulinum toxin: early and long term results. *Dis Colon* 1997; 40:1029-32
7. Watson SJ, Kamm MA, Nicholls RJ, Phillips RKS. Topical glyceryl trinitrate in the treatment of chronic anal fissure. *Br J Surg* 1996; 83:771-5
8. Lund JN, Schofield JH. A randomized, prospective, double-blind placebo-controlled trial of glyceryl trinitrate in the treatment of anal fissure. *Lancet* 1997; 349:11-14
9. Ward DI, Miller BJ, Schache DJ, Cohen JR, Theile DE. Cut or paste? The use of glyceryl trinitrate paste in the treatment of acute and chronic anal fissure. *ANZ Surg* 2000; 70:19-21
10. Schouten WR, Breil JW, Auwerda JJ. Relationship between anal pressure and anodermal blood flow: The vascular pathogenesis of anal fissure. *Dis Colon Rectum* 1994; 37: 664-9
11. Schouten WR, Briel JW, Auwerda JJA, de Graff EJR. Why do anal fissure heal after lateral internal sphincterotomy? *Dis Colon Rectum* 1995; 37:P9
12. Schouten WR, Briel JW, Auwerda JJA, de Graff EJR. Ischaemic nature of anal fissure. *Br J Surg* 1996; 83:63-65

.....★.....

EFFORTS TO REDUCE CAESAREAN SECTION RATE

SOHAIL MAHMOOD CHOUDHARY, AQUEELA AYAZ

ABSTRACT:

The objective of present study was to find out the effectiveness of methods for the reduction of Caesarean section rate (CSR). It was conducted in Obstetric and Gynaecology Unit II, Bahawal Victoria Hospital, Bahawalpur from January 2001 to December 2001. A total of 3753 patients were admitted during the year 2001 in Gynae Unit II, out of which 2170 were obstetric patients. The total number of vaginal deliveries were 1591 (73.32%) and the total number of caesarean sections were 579 (26.68%). With external cephalic version (ECV), 87.5 % success rate was observed in vaginal deliveries. In case of vaginal births after previous Caesarean section the success rate turned out to be 61.31%. Trial of scar, ECV and careful decision about primary Caesarean section significantly reduce the CSR.

KEY WORDS: *Trial of labour, Caesarean section, External cephalic version*

INTRODUCTION

Caesarean section (CS) is the commonest obstetric operation. Substantial increase in CSR was observed, initially in the industrialized countries and currently the same phenomenon is being repeatedly observed in the developing world. In 1965, CSR was reported to be 5% in US which rose to 20 – 25 % within two decades¹. In Europe the frequency of CS has been increasing steadily over the years².

Leading obstetric indications for increasing CSR include cervical dystocia, repeat CS, breech presentation and fetal distress. Problems associated with a scarred uterus may prove detrimental in developing countries because available obstetric facilities are quite different and management of these patients has to be done in a less favourable context. So it is very essential to contain our CSR within reasonable limits³. To achieve this, the following steps must be taken

1. Maximise the number of vaginal deliveries in the first pregnancy.
2. Offer trial of scar (vaginal delivery) to patients with one previous CS.
3. Offer external cephalic version to patients with breech presentation at term.

.....
Correspondence:

Dr. Sohail Mahmood Choudhary
Senior Registrar,
Gynae Unit II B.V.H / QAMC,
Bahawalpur.

In the developing countries like Pakistan, most of the CS are performed as an emergency procedure under suboptimal circumstances. The most profound impact of high CSR is on the management of subsequent pregnancy and labour in patients with previous scars. In less developed countries, because of traditional beliefs and socio-cultural norms, women with previous CS try to avoid the hospital delivery in subsequent pregnancies and engage the services of untrained and unskilled care providers. These patients usually report to hospital with life threatening complications which arise as a result of trial of labour at home⁵.

Trial of scar using the standard guidelines has lead to substantial increase in the number of vaginal births after one previous CS. Success rate with trial of scar depends on the appropriate selection criteria which includes non recurrent previous indication, adequate maternal pelvic dimensions, known uterine incision and absence of any medical/obstetrical complications and fetal macrosomia. In our setup it is very difficult to fulfill the above mentioned conditions because majority of the parturient with previous CS come to the teaching institutions in established or advanced labour with associated medical or obstetrical problems without proper antenatal surveillance. This situation limits the number of the cases which could be subjected to trial of labour. The mode of delivery after previous CS depends on the suitability of the cases for trial of scar and circumstances leading to successful and unsuccessful trial of labour. The fetus is

turned to a head presentation by manipulation on to the mother's abdominal wall by ECV³. By employing this ECV procedure many of CS can be avoided in breech presentation. ECV will reduce breech incidence from 3-4% to 1-2%³.

In all cases of primiparous and multiparous women, we are keeping high threshold for CS except in those cases where it was absolutely indicated. After excluding absolute contraindications to vaginal delivery, every parturient patient subjected to trial of labour to maximise the number of vaginal births even in cases of borderline pelvis. The purpose of this study was to take measure to decrease CSR by subjecting patient to ECV trial of labour.

PATIENTS AND METHODS

This study was conducted in year 2001 in the Department of Obstetrics and Gynaecology unit II at Bahawalpur Victoria Hospital, Bahawalpur. During the study period a total of 3753 patients were admitted in the unit. Out of which 2170 were obstetric patients. 1591 (73.32%) patients delivered vaginally while 579 (26.68%) had CS. Data sources included records of labour room, operation theater, antenatal and postnatal wards.

Absolute contraindications to ECV were

Multiple pregnancy (apart from the second twin after the vaginal delivery of the first)

Antepartum haemorrhage.

Placenta previa.

Ruptured membranes.

Significant fetal abnormality.

Need for caesarean section for other indications.

Relative contraindications to ECV were:

Previous c-section.

Intrauterine growth retardation.

Severe proteinuric hypertension.

Obesity.

Rhesus iso-immunization.

Evidence of macrosomia.

Grand multiparity.

Anterior placenta.

Precious baby.

Previous APH.

Any suspected fetal compromise; unreactive cardiotocogram.

Following were the pre-requisites for ECV:

1. Recent ultrasound to confirm a normal fetus and an adequate liquor volume.
2. Reactive CTG.
3. Informed consent
4. Facilities for the performance of a CS.

RESULTS

Total patients with breech presentation were 65 (3%). Out of which 28 were found to have contraindications for ECV so the remaining 37 patients underwent ECV. In 24 patients ECV was successful. Out of 24 cephalic patients, 21 delivered vaginally but 3 patients required CS due to fetal distress and cervical dystocia.

Total number of patients with previous one CS were 380. Out of these, 150 (39.47%) patients underwent repeat CS due to absolute indications^{7,8}. Trial of labour were given to the remaining 230 (60.53%) patients. 141 (61.31%) patients delivered vaginally and the remaining 89 (39.69%) patients ended up with CS due to scar tenderness, fetal distress, cervical dystocia and failure to progress^{9,10}.

The underlying causative factors for prolonged active phase of dilatation included abnormal uterine action, CPD becoming evident during labour and malpresentations and malpositions. Identified causes of fetal distress were prolonged labour, uteroplacental insufficiency, oligohydramnios and uterine hyperstimulation^{4, 11, 12}.

DISCUSSION

In our study about 26.68% Caesarean section rate was compared to 28.30% rate in other studies. This was as a result of the strategies mentioned in earlier. Maternal age, parity and fetal weight are the factors over which obstetricians have little or no control, and have been shown to be crucial determinants of CSR^{2,4}. Most of the patients included in the study were unbooked, belonged to lower socioeconomic class and illiterate. Study from developed countries revealed 5% to 40% higher CSR in upper social class. In the developing countries, however, at times complicated pregnancies are brought to hospital mostly in emergency, thus Caesarean section remains the only life saving option^{1,2,4}. In our study the major indications of Caesarean deliveries were repeat Caesarean section, cervical dystocia, fetal distress and breech presentation which are in accordance with the conclusions drawn from other studies¹¹.

Currently repeat Caesarean section is the most important cause of increasing CSR. Therefore implementation of a policy of trial of scar after previous one Caesarean section is mandatory to control increasing rate. In our study total of 380 patients with previous one Caesarean section reported. Out of these 230 patients were selected to have trial of labour. The ultimate result in the form of vaginal delivery was calculated to be 61.31% (141 patients) and 38.69% (89 patients) had failed trial, in the form of abdominal deliveries.

The other major indication for Caesarean section was

breech presentation. ECV was implemented after considering contraindications and pre-requisites for ECV, to decrease the CSR in breech presentation. The success rate of converted breech to cephalic presentation in our study is 64.85% (24 patients) with nearly 87.5% of those successfully converted patients, finally delivered in vertex position as mentioned. This was not associated with increased fetal, neonatal or maternal mortality or morbidity. significant reduction in CSR could be achieved by adopting the strategies mentioned earlier and a regular audit of the caesarean sections should be carried out in the departments.

CONCLUSIONS

The following recommendations based on the results of this study have been suggested to increase the prevalence of vaginal births.

1. Trial of scar should be considered in all cases except having absolute indications of repeat Caesarean section. Women with previous one Caesarean section must be educated regarding proper antenatal checkups in future pregnancies so that antenatal complications could be anticipated and handled beforehand and a trial of labour can be instituted.
2. Primary Caesarean section for cervical dystocia and fetal distress should be decided by senior residents in consultation with on call consultants and if caesarean section is to be done it should be in terms of maternal or fetal benefits.
3. While deciding for trial of labour, indication of previous caesarean section, spontaneous onset of labour, Bishop score, presentation and estimated fetal weight should be considered carefully as all these factors were found to be significant determinants of mode of delivery.
4. All patients with breech presentation in antenatal wards should be considered for ECV after 36 weeks of gestation by keeping in mind all the contraindications and pre-requisites for ECV.
5. Departmental policy regarding the strategies should be clear to every resident and caesarean cases should be analysed in depth and reviewed in order to decrease the percentage of CSR.
6. Health care personnel should be trained regarding management of the cases with previous caesarean and breech presentation according to their competency level. Traditional birth attendants (TBA) and staff working at the units where no facilities for emergency caesarean section are available should refer the above mentioned cases to the appropriate centers where trial of scar and ECV can be employed.

REFERENCES

1. Taffel SM, Placek PJ, Liss T. Trends in the United States caesarean section rate and reasons for 1980-1985 rise. *Am J Public Health* 1987; 77 ; 955-9
2. Parazzini F, Pirota N, La-Vecchiac, Fedele L. Determinants of caesarean section rates in Italy. *Br J Obstet Gynaecol* 1992;99: 203-6.
3. Ritchie. JWK Malpositions of the occiput and malpresentation. Dewhurst S Text book of Obstetric and Gynaecology for postgraduates: 5th edition 1995 ; 346-367.
4. Najmi RS. Factors determining route of delivery following one caesarean section. *J Coll Physicians Surg Pak*; 1999; 9:20-23.
5. Najmi Rs. An audit of caesarean sections carried out in a tertiary care maternity unit. *J Coll Physicians Surg Pak*; 2000; 10 : 24-26.
6. Penn PJ. Breech presentation , High Risk Pregnancy ; 2nd edition 1999 ; 1025-1050.
7. Anwer S, Shami N, Akbar N, Asif S. Induction of labour by prostaglandin PGE-2 vaginal tablet in patients with previous caesarean section. *J Coll Physicians Surg Pak* 2002, 12; 208-211.8.
8. Jongen VHWM , Brouwer WK. Vaginal delivery after previous caesarean section for failure of second stage of labour *Br J Obstet Gynaecol*, 1998. 105. 1079-1081.
9. Pal JA. Management of Pregnancy and labour in a scarred uterus. *Specialist. Pakistan J Med Sci*. 1997. 14. 1-4.
10. Lavender T, Allirevic Z, Walkinshaw S. Partogram action line study: A randomized trial. *Br J Obstet Gynaecol*. 1998. 105, 976-980.
11. Bulger T, Howden-Chapman P, Stone P. A cut above the rising caesarean section rate in New Zealand. *N.Z. Med J* 1998;111:30-3
12. Coughlam C, Kearney R, Turner MJ. What are the implications for the next delivery in primigravidae who have an elective caesarean section for breech presentation? *Br J Obstet Gynaecol*; 2002, 109, 624-626.



TRICHOBEZOAR AND GASTRIC POLYPS: A RARE ASSOCIATION

CASE REPORT

ABDUL QADEER, MUHAMMAD TALAT MEHMOOD, SIBGHATULLAH SANGI,

MUHAMMAD SHAHAB ATHAR, SAEED AHMED MAHAR

ABSTRACT:

A 10 year old female child presented with upper abdominal pain and huge abdominal mass in epigastrium extending to both hypochondria and umbilical regions. Investigations revealed a trichobezoar with gastric polyps. At operation, a large trichobezoar occupying almost whole of the stomach was removed along with gastric polyps. Biopsy suggested hyperplastic polyps.

Key words:- Trichobezoar, Gastric polyp

INTRODUCTION

Trichobezoar consists of a mass of ingested hair combined with other fibres. It usually occurs in young women (90%), who pick at their hair and swallow it, having psychiatric disorders.¹ Association of trichobezoar with gastric polyps is very rare and only two cases have been reported in English literature.^{2,3} We are reporting third case of this association.

CASE REPORT

A 10 years old, female child was admitted in the Department of Paediatric Medicine, Unit II, Civil Hospital Karachi in June 2002 through OPD with the complaints of pain in upper abdomen associated with nausea off and on for 5 years; productive cough for 6 months and swelling in upper abdomen for 1 month. Personal history revealed her likelihood to be alone, keeping quiet at home, and short-tempered. She was in habit of putting her hair into the mouth that was noticed by her mother for the last 6 months. Clinical examination revealed anaemia and an intra-abdominal, non-tender firm, mobile, crescentic mass, occupying upper abdomen. Ultrasound (U/S) examination revealed a well-defined mass measuring 6" x 3" in the area of stomach, suggestive of growth. Another U/S examination suggested calcified hydatid or op pancreatic

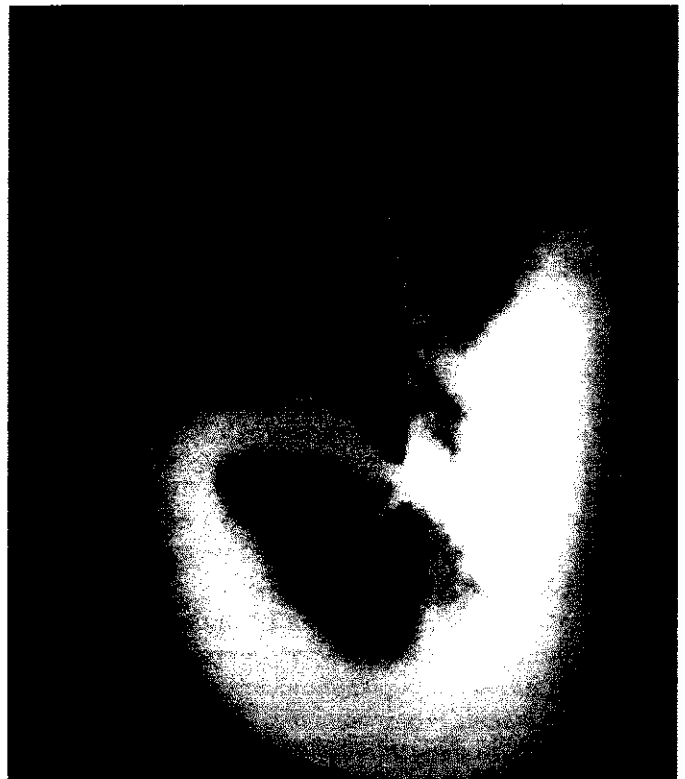

Figure-1: Barium x-ray showing a filling defect by trichobezoar in stomach

.....
Correspondence:

Dr. Abdul Qadeer,
C/O Nisar Ahmed Memon, Tech. Manager,
Al-Karam Textile Mills, Landhi, Karachi.

pseudo cyst. Barium meal examination revealed a large filling defect within the stomach (Figure 1). CT scan suggested a growth with mixed density within the stomach

(Figure II). Gastroduodenoscopy confirmed the diagnosis of large trichobezoar almost occupying the whole of the stomach, associated with multiple polyps within the distal antrum and pyloric region. Patient was referred to us with above diagnosis. Trichobezoar having the cast of stomach was removed at gastrotomy (Figure III) and polyps were excised for biopsy. Histopathology report revealed hyperplastic polyps with no evidence of malignancy. Postoperative recovery was uneventful. Her psychiatric opinion was taken which did not require significant treatment.

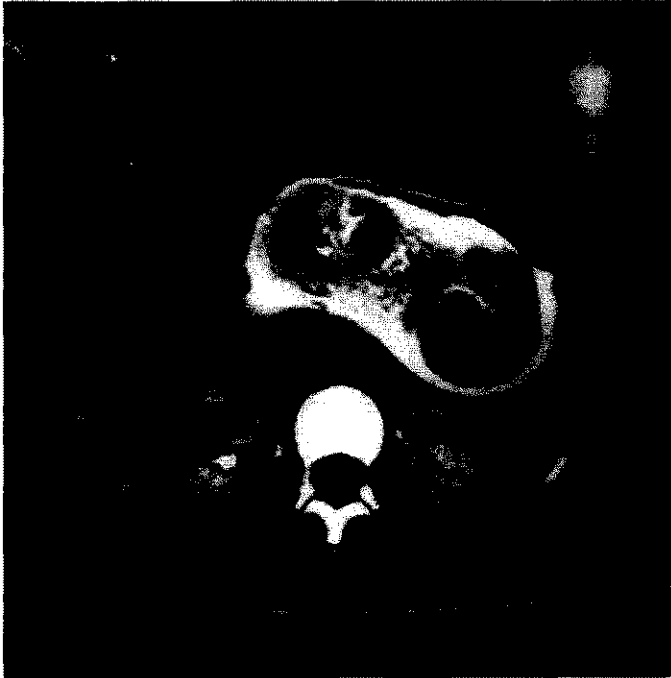


Figure-II. CT scan showing stomach almost filled with trichobezoar

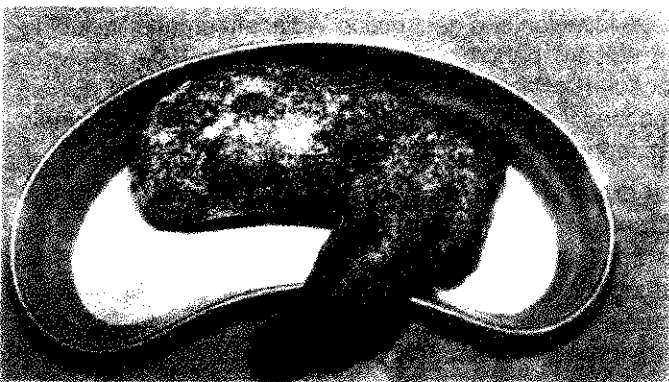

Figure-III: Trichobezoar extracted having the cast of stomach

DISCUSSION:

In our case, although the patient was symptomatic for last 5 years, the diagnosis of trichobezoar was an incidental

finding. That is evident from the literature⁴. For unknown reasons trichobezoars usually do not pass to intestine. It is very rare to find hair in the stool of the patient. No therapeutic agent to dissolve the hair is known and the only choice is surgical removal⁵. The history of putting hair into mouth is positive in our case, but it is not confirmed that the patient actually ate the hair. It is not known why this perverted habit of hair eating occurs but it has been equated to pica syndrome and is considered analogous to nail biting.⁶

Association of bezoars with gastric carcinoma⁷, Menetrier's disease, Zollinger-Ellison syndrome and multiple endocrine adenomata have been reported.^{8,9} In our case, there were multiple polyps of <2cm diameter, located mainly to antral region. There was no evidence of malignancy. There are reports of association between hyperplastic gastric polyps with adenocarcinoma arising from the intervening atrophic gastric mucosa; and the reported ratio is 1 in 26 patients with hyperplastic polyps.¹⁰⁻¹¹

REFERENCES

1. Khan N. Bezoars, A case report & review, *J Coll Physicians Surg Pak* 1992, 2: 103-4
2. Bates C K, Keefe E B, Sahin A. Trichobezoar associated with gastric polyposis. *West J Med.* 1988. 149: 220-3
3. Hossenbocus A, Colin-Jones D G Trichobezoar, gastric polyposis, protein-losing gastroenteropathy and steatorrhea. *Gut.* 1973 ; 14: 730-2
4. Morris P J, Malt R A *Oxford Textbook of Surgery* 1994, vol. 1, 956-7
5. Samad A, Ahmed M, Latif Z Bezoars: A review and report of 2 cases. *J Coll Physicians Surg Pak* 1997, 7: 263-5
6. Bhatnagar V, Mitra D K, Childhood trichobezoars. *Indian J Pediatr* 1984; 51: 489-92
7. Selsinger/Fordtran *Gastrointestinal diseases; Pathophysiology, Diagnosis, Management.* Vol.1, 4th edition, W B Saunders 1989; 741-4
8. Lamerton A J, Trichobezoar: Two case reports- a new physical sign. *Am J Gastroenterol* 1984; 79: 354-63
9. Chakrabarti A K, Singh T D, Joshi K, Malik A K; Menetrier's disease and trichobezoar of stomach – an unusual association. *Postgrad Med J* 1983; 59: 464-73
10. Rosai J, *Ackerman's Surgical Pathology*, 8th edition, St. Louis, C.V. Mosby, 1996, 626-9
11. Sabiston D C, *Textbook of Surgery*, 15th edition, vol. 2: 869-70

.....★.....

XANTHOGRANULOMATOUS PYELONEPHRITIS IN A CHILD

CASE REPORT

AURANGZEB KHAN, INAMULLAH SHAH, AHSIN MANZOOR BHATTI

ABSTRACT:

A case of xanthogranuloma of kidney in a child is presented, which was clinically diagnosed as a case of renal tumor. Nephrectomy with subsequent histopathology revealed xanthogranulomatous pyelonephritis.

Key words:- Xanthogranuloma, Pyelonephritis.

CASE REPORT

A 12 year old boy presented with pain in the left lumbar region of 6 weeks duration. He also gave history of fever on and off for two weeks. On examination, he was afebrile and had tenderness on deep palpation in the left flank. No other abnormality was detected. Urine analysis showed no abnormality and renal function tests were within normal limits. Ultrasonography of abdomen revealed a mass in the upper pole of left kidney. The mass was about 2.5 x 3.5cms, causing a bulge on the surface of the kidney and indentation of the collecting system. No renal calculi were detected. CT scan was done which confirmed the presence of a mass containing cystic areas. The right kidney was normal. Intravenous urography revealed no excretion of dye from the left kidney. DTPA scan confirmed a non-functioning left kidney with normal right renal function. Needle biopsy was inconclusive.

Exploration was carried out through a lumbar incision. A solid mass was found in the upper pole of the left kidney involving the perinephric fat. Left nephrectomy was done and perinephric fascia excised alongwith the suprarenal gland. Postoperative recovery was uneventful. Histopathology revealed xanthogranulomatous pyelonephritis.

DISCUSSION:

Xanthogranulomatous pyelonephritis (XGP) is a serious, debilitating illness characterized by an infectious renal

phlegmon. This disease process shares many characteristics with a true neoplasm in terms of its radiographic appearance and ability to involve adjacent structures or organs. Patients are often immunocompromised in some manner. Schlagenhauser first described XGP in 1916. The first pediatric case was not described until 1963¹.

XGP usually occurs in response to a prolonged renal infection or longstanding renal calculi. Although it is rare in the pediatric population, its incidence in pediatric nephrectomy specimens is approximately 16%². This condition displays properties like a tumour, capable of local tissue invasion and destruction. Adjacent organs, including the spleen, pancreas, or duodenum, may be involved. Because of its invasive property, Malek and Elder³ proposed the following stages of XGP involvement: Kidney, Perinephric fat and adjacent retroperitoneal structures

The gross appearance of XGP is a mass of yellow tissue with regional necrosis and hemorrhage, superficially resembling that of a renal cell carcinoma. The pathognomonic microscopic feature is the lipid-laden "foamy" macrophage accompanied by both chronic- and acute-phase inflammatory cells.

Patients with XGP often appear chronically ill. Symptoms include anorexia, fever, weight loss, and flank pain. The erythrocyte sedimentation rate is frequently elevated. Urine usually has both leukocytes and bacteria present. Renal cell carcinoma may be indistinguishable from XGP radiographically and clinically. Therefore the diagnosis is histopathological.⁴ XGP in childhood exists in both diffuse and focal forms. Diffuse form destroys the parenchyma of the whole kidney leading to a non-functional kidney.⁵

.....
Correspondence:

Dr. Aurangzeb Khan
Combined Military Hospital,
Malir Cantt., Karachi

Medical therapy alone is inadequate to treat XGP. Antibiotics may be appropriate as a temporizing measure for patients requiring medical workup prior to nephrectomy. Similarly, appropriate antibiotics need to be administered prior to operative intervention. XGP is a surgically managed disease requiring either nephrectomy or, in rare circumstances, partial nephrectomy. Extirpation is necessary because the disease usually occurs or results in an infected, nonfunctioning kidney.⁶ These are often challenging cases, particularly if there is local organ involvement. The goal is to remove all the involved granulomatous tissue. If this is not accomplished, the remaining infected tissue may lead to cutaneous fistulae.⁷ Some authors have advocated a role for partial nephrectomy if the disease is limited, kidney functional and therefore amenable to operation.⁸ If the diagnosis is not clear, some authors have recommended an express histopathological examination during surgery.⁹ This becomes more desirable in cases with bilateral focal disease so that partial nephrectomy may be contemplated.

REFERENCES

1. Eastham J, Ahlering T, Skinner E: Xanthogranulomatous pyelonephritis: clinical findings and surgical considerations. *Urology* 1994 43 295-9.
2. Marteinson VT, Due J, Aagenaes I: Focal xanthogranulomatous pyelonephritis presenting as renal tumour in children. Case report with a review of the literature. *Scand J Urol Nephrol* 1996 30 235-9.
3. Malek RS, Elder JS: Xanthogranulomatous pyelonephritis: a critical analysis of 26 cases and of the literature. *J Urol* 1978 119 589-93.
4. Kelemen J. A contribution to radiological diagnostics of xanthogranulomatous pyelonephritis (author's transl) *Rontgenblatter* 1978; 31 439-46.
5. Yazaki T, Ishikawa S, Ogawa Y, Takahashi S, Nemoto S, Rinsho K, Kanoh S, Kitagawa R. Xanthogranulomatous pyelonephritis in childhood: case report and review of English and Japanese literature. *J Urol* 1982; 127 80-3.
6. Nataluk E, McCollough D, Scharling E: Xanthogranulomatous pyelonephritis, the gatekeeper's dilemma": a contemporary look at an old problem. *Urology* 1995; 45: 377-380.
7. Bercowsky E, Shalhav AL, Portis A. Is the laparoscopic approach justified in patients with xanthogranulomatous pyelonephritis? *Urology* 1999 54 437-42.
8. Osca JM, Peiro MJ, Rodrigo M: Focal xanthogranulomatous pyelonephritis: partial nephrectomy as definitive treatment. *Eur Urol* 1997; 32 375-9.
9. Riazantsev EV, Rustsov IuS, Iakimov NA. Xanthogranulomatous pyelonephritis combined with retroperitoneal xanthogranuloma, simulating kidney tumor. *Arch Patol* 1991; 53: 64-5.

.....★.....

UNUSUAL PRESENTATION OF HYDRONEPHROSIS

CASE REPORT

MOHAMMAD ZARIN, NASIR HUSSAIN SHAH KAZMI, MUKHTAR AHMAD,

TAHIR WASIM QURESHI, JAMSHED ALAM

ABSTRACT:

A 15 year old boy having gross abdominal distension of long duration, presented with sudden deterioration of the general condition. He was initially diagnosed as a case of gross ascites but investigations proved it to be a case of unusual presentation of right sided hydronephrosis secondary to pelviureteric junction obstruction. The patient was operated and right sided nephrectomy was performed.

Key words:- Hydronephrosis, Pelviureteric junction obstruction, Nephrectomy.

INTRODUCTION

Idiopathic pelviureteric junction obstruction (PUJO) is common cause of unilateral hydronephrosis. The patient can present with insidious onset of dull aching pain in loin. The hydronephrotic kidney may be palpable. Sometimes the patient can present with attack of renal colic. Pyeloplasty is the treatment of choice for pelviureteric junction obstruction, when a reasonable thickness of functioning parenchyma remains. Nephrectomy is rarely indicated when there is thinning out of cortex and kidney is non functioning. Herein we report an unusual presentation of hydronephrosis.

CASE REPORT

A 15 years old Afghan refugee boy was admitted with gross abdominal distension, general ill health and weight loss. He had this abdominal distension for the last two years but increased during six days time. He had no history of fever, cough, jaundice, diarrhea or blood transfusion.

On examination, he was found to have soft haemic murmur and anaemia. On abdominal examination, he had prominent veins on abdominal wall, grossly distended abdomen and positive fluid thrill. There was no visceromegaly or shifting dullness. Based on clinical examination, he was provisionally diagnosed as a case of

.....

gross ascites may be secondary to cirrhosis of liver. All his baseline investigations were inconclusive, except abdominal ultrasonography which showed a huge cystic mass with internal septae in the whole of abdomen and pelvis. These findings were consistent with loculated fluid collection rather than ascites. Right kidney could not be visualized. The origin of the cystic mass could not be ascertained. About ten liters of straw coloured fluid was aspirated which was transudate on biochemical examination, no AFB seen and no growth on culture found.

Surgeon's opinion was then sought. CT scan of abdomen showed grossly hydronephrotic right kidney secondary to pelviureteric junction obstruction. Cortical mass of the kidney was reduced to fine septae. Intravenous urography showed nonfunctioning right kidney. After preparing and counseling with the patient and attendants, it was decided to perform right sided nephrectomy. He was opened through an extraperitoneal approach. The pelvicalyceal system of right kidney was grossly dilated containing 20 liters of fluid. A thin rim of cortical tissue was present on the posterolateral aspect of the cystic mass. The fluid was aspirated, ureter identified which was of normal caliber and right nephrectomy performed. A tube drain put in the extraperitoneal space.

The post operative course of the patient was uneventful, except he developed slight abdominal distension on 3rd post operative day and x-rays showed free gas in the peritoneal cavity. It was considered to be due to unnoticed perforation in the peritoneum and was treated

Correspondence:

Dr. Mohammad Zarin
Surgical Specialist, D.H.Q. Hospital,
Battagram, Hazara, N.W.F.P.

conservatively by nasogastric suction and intravenous fluids. The abdominal distension settled and patient was allowed orally on fifth post operative day. Drain was removed on sixth post operative day after remaining dry for more than 24 hrs. he was discharged home on 8th post operative day with the advice of follow up visit.

DISCUSSION:

pelviureteric junction obstruction is one of the most common congenital urological anomalies. It is the most frequent cause of upper urinary tract obstruction in children. Anderson and Hynes, described the dismembered pyeloplasty, the most common reconstructive procedure used today for pelviureteric junction obstruction¹. The ureteropelvic junction can also be reconstructed by flap procedure devised by Culp and Scardino². Thompson and associates³ suggested a capsular flap pyeloplasty when sufficient pelvic tissue is not present for repair.

Nephrectomy is indicated in selected cases when there is complete loss of cortical tissue and or pyonephrosis. The approach to the kidney can be made through the flank in the extra peritoneal space but in muscular and obese patients, transperitoneal approach may be necessary. Long term follow is mandatory after nephrectomy as patient is left with one kidney only.

REFERENCES

1. Anderson JC, Hynes W : Retrocaval ureter . A case diagnosed preoperatively and treated successfully by a plastic operation Br J urol. 1949; 21 : 209.
2. Culp OS , De Weerd JH : A pelvic flap operation for certain type of ureteropelvic obstruction. Preliminary report : Mayo Clin Proc. 1951; 26 : 483.
3. Thompson IM , Baker J , Robards VL Jr , Kovacsil Ross G Jr : Clinical Experience with renal capsule flap pyeloplasty. J Urol. 1969; 101: 487.

.....★.....

RIGHT INGUINAL REGION LIPOMA

CASE REPORT

MUBASHIR HUSSAIN SHERAZI, MASOOD AHMAD BUTT

ABSTRACT:

Lipomas are seen commonly in the surgical out patients. Inguinal region lipoma is a rare occurrence. A fifty years old man presented with pain in the inguinal region for two years and a mass in the inguinal region for three months. An ultra-sound and CT scan confirmed a right pelvic mass extending into the inguinal region along the course of the psoas muscle. FNAC confirmed the diagnosis as a lipoma. Excision was successfully done. Histopathology confirms the diagnosis of lipoma.

Key words:- Lipoma, Inguinal region, Soft tissue tumor

INTRODUCTION

Lipomas are the commonest of benign tumors. Occasionally lipomas appear in large numbers subcutaneously and are tender. Lipoma is a slow growing tumor composed of fat cells of adult type. It can occur anywhere in the body where fat is found. Most Lipomas are painless, but some give rise to an aching sensation Clinically circumscribed, lipomas are classified according to their location as subcutaneous etc. Herein we report case of lipoma at an unusual site.

CASE REPORT

A 55 years old male presented with pain in right inguinal region for two years. Pain was burning in nature, mild to moderate in intensity and originating in right lumbar region. Pain increased on standing during long hours of duty. Pain relieved on taking rest and lying flat. Pain radiated to the right side of the back and right lumbar region. For the last three months patient noticed a swelling in the right inguinal region, which gradually increased in size. There was a feeling of discomfort and fullness in the upper thigh. There was no history of discharge from the swelling. The skin over the swelling remained normal. There was no history of gastrointestinal or urinary complaints. Rectal examination was insignificant. Local examination revealed a large smooth surfaced swelling in the right iliac fossa extending through the right ilio-inguinal region down to the upper part of the right thigh. Temperature over the swelling was normal. The swelling had well-defined margins and it was fixed to the under lying tissue. There was no cough impulse or bruit.

.....
Correspondence:

Dr. Mohammad Zarin
Surgical Specialist, D.H.Q. Hospital,
Battagram, Hazara, N.W.F.P.

On ultrasound examination at a complex heterogeneous mass ovoid in outline, 10 x 5.7 x 6.7 cm in dimensions arising from the floor of right iliac line and extending upwards into the right iliac fossa found. The mass had coarse fossa echo texture. There was no calcification. C.T scan revealed a lipoma. FNAC confirmed the diagnosis of lipoma. The lipoma was excised using the right supra-inguinal retroperitoneal approach under spinal anesthesia. It was observed that it was a retroperitoneal lipoma extending from right iliac fossa within the iliac sheath extending distally below the inguinal region into the right thigh. The tumor was removed enbloc without any damage to the adjacent structures. The gross examination showed the tumor measuring 10x 6x 7 cm and weighed 1.2 kg. The postoperative hospital stay was uneventful and patient was discharged on the 4th postoperative day. The patient has been followed up for two years and there was no recurrence of the disease and there is no more pain.

DISCUSSION:

Lipoma of the inguinal region especially in the psoas sheath is rare to find. No data is available regarding the exact incidence of lipomas in the inguinal region. The presence of a spermatic cord lipoma is not an uncommon finding during inguinal hernia repair. In a study of twenty-five pre-peritoneal hernias repair, two patients had a lipoma of the cord and the absence of the peritoneal sac extending into the deep ring.³ Weight of lipomas varies from few grams to kilograms. A case of huge primary retroperitoneal liposarcoma weighing 16.5 Kg was reported from Pakistan Institute of Medical Sciences Islamabad, Pakistan.⁴ Lipomas usually represent an easy job for the surgeon for its removal if at all needed.

REFERENCES

1. Harold E, Sir Roy C, Christopher W, The Skin and the Adnexae. Lecture Notes on General Surgery: Ninth edition: Blackwell Science:1998; 48-50
2. RCG Russell, Norman S.W, Christopher JKB. Tumours. Cysts. Ulcers. Sinuses. Bailey and Love's Short Practice of Surgery. Arnold International edition: 23rd edition: 2000; 151-152
3. Ponka JI. Hernias of the abdominal wall. Philadelphia, Pennsylvania. W.B. Saunders, 1980
4. Syed AS, Muhammad AZ, Shahid AK, et al. Primary Retro-peritoneal Liposarcoma, J Coll Physicians Surg Pak, 2001; 11 : 719-20

