

# Gastric Volvulus Caused By Strangulated Paraesophageal Hernia In Pregnant (3<sup>rd</sup> Trimester) Lady

Khalid Ibrahim,<sup>1\*</sup> Riffat Naqvi,<sup>1</sup> Sarah Fatima,<sup>1</sup> Bushra Aman<sup>1</sup>

## ABSTRACT

*Para esophageal hernia occurs without symptoms or present in emergency. We present a case of 27 years old pregnant (3<sup>rd</sup> trimester) lady, referred by gynecologist after treating conservatively excessive vomiting and pain epigastrium (3 days duration) on the basis of pregnancy associated –peptic ulcer disease with no past history of heart burns with mild hydronephrosis left kidney on ultrasound, mildly raised total leukocyte count and serum amylase. She remained well for two days, and then suddenly developed hematemesis and severe epigastric pain, difficulty in breathing and localized tenderness with hypotension and tachycardia. Upper GI endoscopy was done showing necrotic erythematous patches in fundus area and endoscope could not be negotiated beyond that point. After counseling of patient and husband regarding fetus safety, upper GI gastrograffin study was done, which showed dumbbell shaped stomach with central constriction. CT scan chest and abdomen with contrast revealed half of the stomach within left chest.*

*Emergency laparotomy was performed which showed tight esophageal hiatus with strangulated paraesophageal hernia leading to gastric volvulus more than 3/4<sup>th</sup> of stomach along with omentum gangrene leaving small portion of pyloric area intact and foul-smelling fluid in left chest. Total gastrectomy, closure of duodenal stump, feeding jejunostomy, exclusion of esophagus due to friable gastroesophageal junction and chest intubation were done. Patient was managed on ventilator support along with gynecological care and oesophagojejunostomy Roux-en-Y was planned later on due to condition of patient and friability of tissues. A high index of suspicion should exercised in unusual episodes of excessive vomiting in a pregnant lady in third trimester.*

*Key words* Strangulated paraesophageal hernia, Volvulus, Vomiting in pregnancy.

## INTRODUCTION:

Hiatal hernia occurs when part of stomach pushed up through esophageal hiatus into chest. Four types of hiatal hernias are generally found; sliding, paraesophageal, combined and complex. Para esophageal hernia comprises of 5% of all hiatal hernias.<sup>1</sup> In paraesophageal hernia gastro esophageal junction remains within abdomen and in sliding hernia there is shift of gastroesophageal junction with chest above diaphragm.

Paraesophageal hernias usually present with life threatening symptoms and sliding hernia presents with GERD, early satiety or without any symptoms.<sup>2</sup>

## CASE REPORT:

A 27 years old pregnant (3<sup>rd</sup> trimester) female referred by gynecologist after treating conservatively for two days the complaints of excessive vomiting, pain epigastrium on the basis of pregnancy- associated peptic ulcer disease. She suddenly developed hematemesis, severe epigastric pain, difficulty in breathing with blood pressure of 90 / 60 mmHg, pulse rate of 115/min and respiratory rate of 30/min and O<sub>2</sub> saturation 90-94% on oxygen 8L/min. Blood total leukocyte count 19×10<sup>9</sup>/l, Hb%7g/dl. After counseling the patient and husband about fetus safety and consulting gynecologist, upper GI endoscopy was done, showing necrotic erythematous patches in fundus and endoscope could not be negotiated beyond fundus. Gastrograffin studies showed dumbbell-shaped stomach. Contrast

<sup>1</sup> Department of Surgery Combined Military Hospital, Malir Cantt. Karachi.

## Correspondence:

Dr. Khalid Ibrahim <sup>1\*</sup>  
Department of Surgery  
Combined Military Hospital, Malir Cantt  
Karachi  
E mail: khalidibrahimsurg@hotmail.com

enhanced CT chest, abdomen showed half of stomach within left chest with fluid all around. Emergency laparotomy was performed which revealed tight esophageal hiatus with strangulated paraesophageal hernia, volvulus of stomach with gangrene of 3/4<sup>th</sup> of stomach with omentum leaving small portion of pyloric area intact, friable gastroesophageal junction, foul smelling fluid in left chest. Tight hiatal opening was widened carefully and gangrenous stomach along with omentum was carefully pulled down. Total gastrectomy, closure of duodenal stump in two layers, feeding jejunostomy, esophageal exclusion over Foley catheter, and repair of esophageal hiatus, three sided wide drains and left side chest intubation were done. Patient was

managed on ventilator, jointly cared by critical care specialist, gynecologist. Unfortunately, patient showed bad obstetrics course postoperatively after reviewed by gynecologist and emergency cesarean section was done and dead fetus was taken out. Patient remained in ICU for three weeks and esophagojejunostomy Roux-en-Y was planned after stabilization of general condition of the patient.

#### DISCUSSION:

Hiatus hernia is pushing up of stomach through esophageal hiatus of diaphragm. Four types of hernias i.e. sliding (type I), paraesophageal with organo-axial rotation of stomach (type II), combining elements from both types with meso-axial rotation of stomach (type III) and complex (type IV) containing herniating abdominal viscera other than stomach into thoracic cavity. Common risk factors are obesity, old age, major trauma etc.<sup>3</sup>

Sliding hernia may be asymptomatic or present with GERD, and early satiety. Para esophageal hernia may present with life threatening symptoms such as hemorrhage, volvulus with obstruction, perforation or gangrene in one third of patients. Diagnostic difficulties arise as epigastric pain occurs in many conditions related to cardiac, thoracic and abdominal pathologies especially in pregnancy. So liaison among surgeons and physicians is very important.<sup>4</sup>

Blood tests such as serum amylase, cardiac enzymes, ABG's, ECG are helpful in ruling out of differential diagnosis. Chest x-ray is important in giving the clue regarding intra-thoracic abdominal viscera. CT scan is the investigation of choice in establishing the diagnosis.<sup>5</sup>

Acutely strangulated paraesophageal hernia is really challenging for the surgeons especially in pregnant ladies as fetal death risk is very high. In emergency cases, laparotomy after resuscitation is the right approach. It is recommended that paraesophageal hernia should be operated electively as early as possible to avoid morbidity and mortality. The annual probability of emergency surgery in patients with paraesophageal hernia is 1%.<sup>6</sup> Some surgeons are of the opinion that role of elective surgery is debatable due to low incidence of life threatening complications. Patients who underwent laparoscopic repair of paraesophageal hernia had 0.5% mortality, low morbidity and 2.5% recurrence rate.<sup>7</sup> Our case was challenging as stomach was necrotic and extensive surgical procedure was performed. Though woman survived but her fetus died in postoperative period.

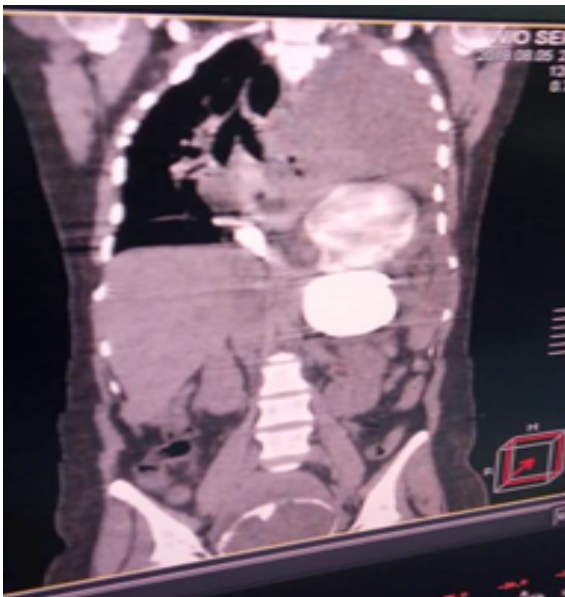


Fig I: CE CT Scan chest/abdomen showing paraesophageal hernia with gastric volvulus

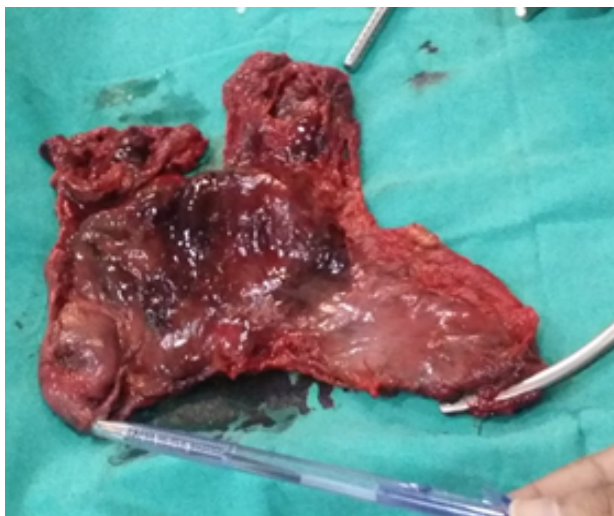

Fig II: Per operative findings of gangrenous stomach

**CONCLUSION:**

A high index of suspicion should be kept in mind in patients with strangulated paraesophageal hiatal hernia who present with excessive vomiting, severe pain epigastrium and difficulty in breathing especially in pregnant lady to avoid morbidity and mortality to two lives, the mother and fetus.

**REFERENCES:**

1. Callaway JP, Vaezi MF. Hiatal and paraesophageal hernias. 2018;16:810-13
2. Parkera J, Sabanathana S. Incarceration and perforation of a sliding hiatal hernia: Report of a case. *Gastroenterol Res.*2011;4:228-30.
3. Low DE, Simchuk EJ. Effect of paraesophageal hernia repair on pulmonary function. *Ann Thorac Surg.* 2002;74:333-7.
4. Schwenter L, Wulff C, Kerienberg R, Herr D. Exacerbation of a maternal hiatus hernia in early pregnancy presenting with symptoms of hyperemesis gravidarum: a case report and review of literature, *Arch Gynecol Obstet.* 2011;283:409-14.
5. Roman S, Kahrilas PJ. The diagnosis and treatment of hiatal hernias. *BMJ.* 2014;349:6154.
6. Bonvahab M, Mitchell P, Church N, Debrn E. Management of acute paraesophageal hernia. *Surg Endosc.* 2009;23:225-59.
7. Pierre A, Luketich J, Fernando H, Christie N, Buenventura P, Little V, Schauer P: Results of laparoscopic repair of giant paraesophageal hernias. 200 Consecutive patients. *Ann Thoracic Surg.* 2002;74:1909-15.

Received for publication: 26-11-2018

Accepted after revision: 30-04-2019

Author's Contributions:

Khalid Ibrahim: Manuscript writing.

Riffat Naqvi: Data collection.

Sarah Fatima: Data collection.

Bushra Aman: Data collection.

Conflict of Interest:

The authors declare that they have no conflict of interest.

Source of Funding:

None

How to cite this article:

Ibrahim K, Naqvi R, Fatima S, Aman S. Gastric volvulus caused by strangulated paraesophageal hernia in pregnant (3<sup>rd</sup> trimester) lady. *J Surg Pakistan.* 2019;24(2):104-6. Doi:10.21699/jsp.24.2.12.