

Dynamization Versus Static Antegrade Intramedullary Interlocking Nail In Femoral Shaft Fractures

Muhammad Khalid, Imtiaz Hashmi, Sohail Rafi, Muhammad Idrees Shah

ABSTRACT

Objective To compare the primary dynamic interlocking technique with static interlocking method for femoral shaft fractures in terms of bony union.

Study design Quasi experimental study.

Place & Duration of study Department of Orthopaedic Surgery, Ziauddin University Hospital Karachi, from March 2012 to August 2013.

Methodology All patients with closed femoral shaft fractures were treated by closed reamed intramedullary (IM) interlocking nail. They were divided into two equal groups. Group I (Dynamization group) patients underwent primary dynamization and in Group II (Static group) patients the static nail was used. Both groups were divided into subgroups on the bases of post reduction intrafragmental gap less than or more than 3mm on x-ray. The surgical procedure and postoperative protocols were same for both the groups, with the exception of interlocking mode. The outcome was measured using Thorensen clinical criteria. Bony union, time of union, delayed union, nonunion, implant breakage and leg shortening were recorded.

Results A total of 64 patients were included, 32 in each group. Mean time of union was same in dynamic group and static group with post reduction intrafragmental fracture gap < 3mm. In the dynamic group with post reduction intrafragmental fracture gap=3mm, one case of nonunion was noted. In static group two cases of delayed union and one case of nonunion were noted in sub group with post reduction intrafragmental fracture gap=3mm.

Conclusion Dynamization significantly shortened the mean time to union in femoral shaft fracture with intrafragmental gap =3mm, though it did not significantly affect the union rate of the femoral shaft fractures as compared to static close intramedullary interlocking nailing.

Key words Femur fracture, Intramedullary nail, Static locking, Dynamization.

INTRODUCTION:

Femur shaft fractures are a major cause of morbidity and mortality in patients with lower extremity injuries.¹⁻³ Femoral shaft fractures occur in a bimodal distribution. Femoral shaft fractures are usually the result of high velocity trauma and are more common

in the younger population. Fractures usually occur as a result of motor vehicle accidents.⁴⁻⁶

On the other hand, as the population ages, the femoral shaft fractures represent a major health problem in the elderly population due to osteoporosis. The outcome may be extremely poor if there is prolonged bed rest.^{2,5} The incidence of femoral fractures is reported as 1 fracture per 10,000 people.⁷⁻⁹ Intramedullary nailing has become the gold standard for the treatment of femoral shaft fractures.^{1,2} Major advantages of intramedullary nailing include a minimally invasive operative technique with lower impairment of the perfusion at the fracture site and

Correspondence:

Dr. Muhammad Khalid
Department of Orthopedic Surgery
Ziauddin University Hospital
Karachi
E-mail:drmkarain@gmail.com

a high biomechanical stability. The rate of major complications for intramedullary nailing is low.

Techniques of intramedullary nailing incorporate antegrade and retrograde, reamed and unreamed methods, as well as static and dynamic locked nail.^{2,3,6} Static locking involves placement of two proximal and distal locking screws, which prevent malrotation and shortening.⁹⁻¹¹ Dynamization is done with one locking screw placed in proximal dynamization screw hole and two locking screws placed on distal side of the fracture. This allows early weight bearing and early fracture union.^{11,12} Dynamization is important for early mobilization, allowing both hip and knee motion. This method of treatment has yielded good results and remains the procedure of choice worldwide for femur shaft fracture.^{13,14} This study was designed to analyze radiographic outcomes in patients who had undergone dynamization with those that had static nailing with post reduction intrafractural gap less or more than 3mm on x-ray.

METHODOLOGY:

This was a quasi experimental study conducted between March 2012 and August 2013. All patients in the Department of Orthopaedic Surgery, Ziauddin University Hospital for IM femur nailing were enrolled. Ethics Committee approval was obtained. Inclusion criteria were clinically and radiologically diagnosed cases of femoral shaft fracture in Winquist and Hansen classification grade 1, 2 and 3 fracture. Patients with open fracture, pathological fracture and with poly trauma, were excluded. Russell Taylor closed reamed antegrade intramedullary interlocking nails were placed in all the patients.

Patients were randomly divided into two main groups. The group I patients underwent nail dynamization (dynamized group). The group II patients had static nail placement (static group). Data collected prospectively were entered in a computerized database and were subsequently analyzed. Variables studied included demographics, type of locking performed, postoperative complications, mode of mobilization, impairment of knee and ankle joint range of motion and time to union. The outcome was measured on clinical based outcome; the Thorensen criteria. Delayed union was defined as the failure of the fracture to progress to union by six months, whereas nonunion was defined as no progression of the fracture to osseous healing by nine months and a secondary intervention was necessary.

In both the groups, partial weight bearing was

allowed within first postoperative week. Full weight bearing was encouraged as soon as the inflammation subsided and any residual pain was well tolerated by the patient, usually within three weeks from the date of surgery. Patients were regularly followed up in outpatient department at week 2, 6, 12, 18 and thereafter every 2 weeks till union achieved and at 9 month as indicated by the patient's condition, or longer if necessary. Radiological union was defined as the presence of bridging callus in at least 3 out of 4 cortices as revealed by anteroposterior and lateral projections. The minimum follow up period was 12 months (range 12–18).

Data was analyzed using the SPSS version 10. Mean and standard deviation were computed for quantitative variables. Comparisons between qualitative variables were performed by Chi square test and Friedman test. Pearson's correlation was used to analyze the relationship between quantitative variables. A p value <0.05 was considered statistically significant.

RESULTS:

Out of 93 patients with femur shaft fractures who were treated in our institution during the pre-specified period, 64 met the inclusion criteria and managed with Russel Tylor closed reamed intramedullary interlocking nail. They were randomly assigned to one of two groups depending on the osteosynthesis technique used: the dynamization group (32 cases), and the static group (32 cases). There were 57 (89.1%) males and 7 (10.9%) females with male to female ratio of 8:1. Road traffic accident was responsible for 52 (81.2%) cases. In 12 (18.8%) patients fractures were caused by fall from height. The demographic details and clinical characteristics were homogeneous and comparable between the two groups. The average age of the patients was 28.73 ±6.41 year (95% CI: 26.34 to 31.13). The average hospital stay was 4.3±1.27 days (95% CI: 3.03-5.57). Three patients were lost to follow up and one died during the study. For final analysis 60 patients were left, 30 in each group.

At the 2nd week, mild pain was observed in 44 (73.3%), moderate pain in 12 (20%) and severe in 4 (6.7%) patients. Pain was significantly reduced at 12th week and thereafter no pain was observed in any patient (p=0.0005). The wound was clean in 52 (86.7%) patients and 8 (13.3%) had superficial infection at 2nd week while all wounds were clean at 4th week. Deep infection was not found in any case. Patients were started on protected toe-touch weight bearing within first week of operation as they felt comfortable. All patients except two (3.3%)

started partial weight bearing in first week and all patients started full weight bearing in third week after surgery.

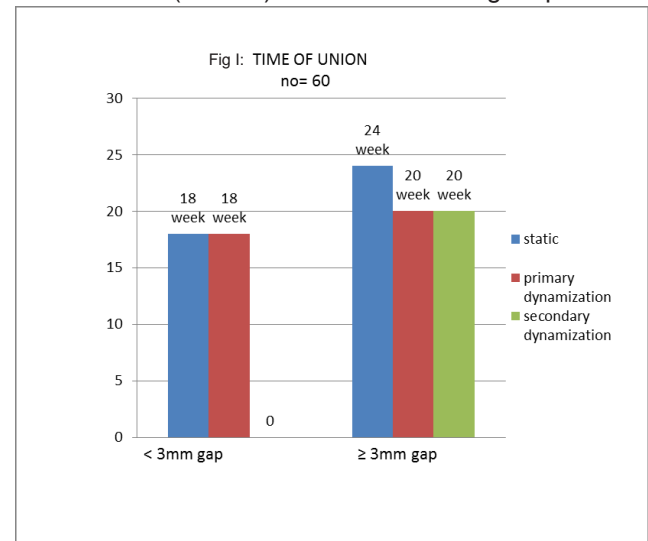
In static group out of 30, 19 (63.3%) patients had post reduction intrafragmental gap < 3 mm and 11 (36.6%) patients had intrafragmental gap = 3mm on x-ray. In dynamic group out of 30, 16 (53.3%) patients had post reduction intrafragmental gap < 3mm and 14 (36.7%) had intrafragmental gap = 3mm on x-ray. The mean time to union was 20 week in the dynamic group as compared to static group where it was 24 week in patients with intrafragmental fracture gap of = 3mm on post operative x-ray (Fig-I). There were no significant differences between the union time in the dynamized and static groups with intrafragmental gap <3 mm on postoperative x-ray.

In static group, 19 (63.3%) patients and in dynamic group 16 (53.3%) patients with post-surgery intrafragmental gap <3 mm, showed sign of union on x-ray at 18th week. In static group 11(36.7%) had postoperative intrafragmental gap = 3mm. Out of these 4 (36.3%) cases had union at 24th week, 2 (18.2%) had delayed union and 01 (9.0%) was of nonunion on x-ray. Four (36.3%) cases were united at 20th week after surgery with implant breakage (distal screw) noted at 12th week after surgery. These 04 cases were dynamized by itself after screws breakage and included in dynamized group. In dynamised group, 14 (66.6%) patients had postoperative intrafragmental gap of = 3mm. There were four cases of secondary dynamization added in this group. One (5.6%) case showed nonunion and 17 (94.4%) cases showed sign of union on x-ray at 20th week after surgery (table I).

In static group all patients had limb shortening <1cm as compared to dynamic group that showed >2cm shortening in 4 (12%) out of 34. The range of motion at hip joint in terms of flexion, extension, abduction, adduction, internal rotation and external rotation were noted on every follow up visit and final outcome was measured at 24th week .The mean range of motion in terms of flexion and extension at hip were 121°± 1.78° and 11.1 ± 1.5° respectively

at 24th week. Flexion and extension significantly increased and were close to the normal range of flexion and extension at 24th week of follow up (Friedman test; p<0.01). The average abduction was 9.3 ±4.5° at 2nd week and average abduction was 36.4 ±5.1 ° at 24th week which showed that abduction was significantly increased and closed to the normal range of abduction. (Friedman test; p= 0.0001). The average adduction was 10.3± 3.5° at 2nd week and average adduction was 24.2±4.5° at 24th week which also showed that adduction was significantly increased and close to normal range of adduction at 24th week of follow-up visit (Friedman test; p= 0.0001). Average internal and external rotation in extension of hip joint was significantly increased and closed to the normal range of internal and external rotation in extension. The range of flexion and extension at knee was almost normal at 24th week of follow-up visit (table II).

On clinico-radiological evaluation at 9 months after surgery excellent results were noted in 19 (63.3%) patients in static group and 16 (53.3%) patients in dynamized group with postoperative intrafragmental gap < 3 mm. In patients with postoperative intrafragmental gap = 3 mm, excellent results were seen in 3 patients (42.8%) of static group and 12 (66.7%) in dynamized group, good results in 2 (28.6%) cases of static group and 5



Outcome	Static (n=11) with = 3mm gap	Dynamized (n=14) with = 3mm gap
Delayed union	2 (18.2%)	0 (0%)
Non union	1 (9.0%)	1 (7.1%)
Limb shortening	0 (0%)	4 (28.6%)
Implant breakage	4 (36.4%)	0 (0%)

Table II: Range of Motion at Hip Joint (Final outcome at 24 th week)				
Normal range	Mean ± SD	Median (IQR)	Mean Ranks	p value
Flexion (0 - 120°)	121 ± 1.78	120 (10)	5.89	Chi square: 108.82 df= 6 p=0.0001
Extension (5°- 20°)	11.1 ± 1.5	10 (2)	5.63	Chi square: 94.97 df=6 p=0.0001
Abduction (40°)	36.4 ± 5.1	100 (10)	2.15	108.1 df=6 p=0.0001
Adduction (0 - 25°)	24.4±4.5	110 (10)	3.30	Chi square: 111 df=6 p=0.0001
Internal rotation (35°)	34.2±2.4	30 (06)	5.9	Chi square: 108.5 df=6 p=0.0005
External rotation (45°)	40.2±6.2	40 (11)	5.85	Chi square: 109.5 df=6 p=0.0005

Table III: Clinical Based Outcome (Thorensen's Criteria)		
Outcome	Static Group (n=30)	Dynamized Group
< 3mm post reduction gap		
Excellent	19 (63.3%)	16 (36.7%)
= 3mm post reduction gap		
Excellent	3 (42.8%)	12 (66.7%)
Good	2 (28.6%)	5 (27.8%)
Fair	1 (14.3%)	0 (0%)
Poor	1 (14.3%)	1 (5.5%)

(27.8%) cases of dynamized group, fair results in 01(14.3%) patient in static group, and poor results in 01 (14.3%) patient in static group and 01(5.5%) in dynamized group (table III).

DISCUSSION:

The study showed that dynamization technique allowed the contact between the bone fragments in order to avoid interfragmentary gaps. The encouragement of early weight bearing facilitated prompt dynamization of the fracture fragments and promoted the formation of good periosteal callus as reported by others.^{15,16} IM nailing can be categorized biomechanically as dynamic or static. Dynamic stabilization implies that intact cortical bone of the major proximal and distal fragments of the fracture can share a portion of axial and rotational forces across the fracture site, thereby preventing shortening and rotation. Static interlocking describes the interlocking construct in which both the proximal and distal interlocking screws have been inserted.

Shortening and malrotation are controlled by transferring the axial and rotational stresses through the nail rather through the site of fracture.¹⁷⁻¹⁸

In our study, the dynamization group exhibited a faster time to union and showed a less number of postoperative complications. Evidence from two international studies suggests that dynamization of intramedullary nailing and static IM nailing for femoral shaft fractures appears to be comparable with regards to risk of nonunion, nail breakage, and limb shortening. There was no difference in the risk of nonunion based on treatment in either study. Time to union was significantly shorter when dynamization was done. In one study no breakage was reported with dynamized IM nailing and 4% with static IM nailing in another study.^{11,20}

In reviewing the literature it was found that 4% of patients had shortening following dynamization compared with 0% of patients with static IM

nailing.^{19,20} We found that a post-reduction fracture gap of = 3 mm with a statically-locked nail was associated with significantly longer time to union than with a dynamically locked nail. Furthermore, there was no significant difference in the time to union between fractures treated by static and dynamic fixation when the post-reduction gap was < 3 mm. Our experience substantiates other reports in literature that dynamic intramedullary femoral stabilization showed good results in cases with post-reduction gap =3 mm as compared to the static group.

CONCLUSIONS:

Intramedullary interlocking nailing was safe and effective treatment modality for the treatment of fractures of the femoral shaft. Intramedullary nailing with dynamization reduced time to union, complications, and re-operations.

REFERENCES:

1. Beaty JH, Austin SM, Warner WC, Canale ST, Nichols L. Interlocking intramedullary nailing of femoral-shaft fractures in adolescents: preliminary results and complications. *J Pediatr Orthop* 1994;14:178-83.
2. Morshed S , Miclau T, Bembom O, Cohen M, Knudson MM, Colford JM. Delayed internal fixation of femoral shaft fracture reduces mortality among patients with multisystem trauma. *J Bone Joint Surg Am.* 2009;91:3-13.
3. Stojiljkovic P, Golubovic Z, Mladenovic D, Micic I, SasaKaralejic, Kostic I, et al. External fixation in primary treatment of the femoral shaft fracture. *Acta Fac Med Naiss* 2007;24: 21-6.
4. Brumback RJ, Ellison PS, Poka A, et al. Intramedullary nailing of open fractures of femoral shaft. *J Bone Joint Surg Am.* 1989;71:1324-30.
5. Harris I, Hatfield A, Donald G, Walton J. Outcome after intramedullary nailing of femoral shaft fractures. *ANZ J Surg.*2003;73: 387-9.
6. Whittle AP, Wood II GW: Fractures of lower extremity. In: Canale TS (ed.): *Campbell's Operative Orthopaedics*. 10th ed. Mosby, St

- Louis London Philadelphia. 2003;3:2825-72.
7. Nowotarski PJ, Turen CH, Brumback RJ, Scarborough JM. Conversion of external fixation to intramedullary nailing for fractures of the shaft of the femur in multiply injured patients. *J Bone Joint Surg Am.* 2000;82:781-8.
8. DeFranco MJ, Recht M, Schils J, Parker RD. Stress fractures of the femur in athletes. *Clin Sports Med.* 2006;25:89-103
9. Jain P, Maini L, Mishra P, Upadhyay A, Agarwal A. Cephalomedullary interlocked nail for ipsilateral hip and femoral shaft fractures. *Injury.* 2004; 35:1031-8.
10. Arpacioğlu MO, Akmaz I, Mahiroğulları M, Kiral A, Rodop O. Treatment of femoral shaft fractures by interlocking intramedullary nailing in adults. *Acta Orthop Traumatol Turc.* 2003;37: 203-12.
11. Basumallick MN, Bandopadhyay A. Effect of dynamization in open interlocking nailing of femoral fractures. A prospective randomized comparative study of 50 cases with a 2-year follow-up. *Acta Orthop Belg.* 2002;68:42-8.
12. Brumback RJ. Intramedullary nailing of femoral shaft fractures. Part II: Fracture-healing with static interlocking fixation. *J Bone Joint Surg Am.* 1988;70:1453-62.
13. Brumback RJ. The rationales of interlocking nailing of the femur, tibia and humerus. An overview. *Clin Orthop.* 1996;324:292-320.
14. Dagrenat D, Moncade N, Cordey J, Rahn BA, Kempf I, Perren SM. Effects of the dynamization of static bolt nailing. In vivo experimentation. *Rev Chir Orthop Reparatrice Appar Mot.* 1988(S)2;100-104.
15. Egger EL, Gottsauner-Wolf F, Palmer J, Aro HT, Chao EY. Effects of axial dynamization on bone healing. *J Trauma.* 1993;34:185-92.
16. Wu CC1, Shih CH. Effect of dynamization of a static interlocking nail on fracture healing. *Can J Surg.* 1993;36:302-6.
17. Klemm KW, Börner M. Interlocking nailing of complex fractures of the femur and tibia. *Clin Orthop Relat Res.* 1986;212:89-100.

18. Kempf I, Grosse A, Beck G. Closed locked intramedullary nailing. Its application to comminuted fractures of the femur. *J Bone Joint Surg Am.* 1985;67:709-20.
19. Holst-Nielsen. Dynamic intramedullary osteosynthesis in fractures of the femoral shaft. *Acta Orthop Scand.* 1972;43:411-20.
20. Tigani D, Fravisini M, Stagni C, Pascarella R, Boriani S. Interlocking nail for femoral shaft fractures: is dynamization always necessary? *Int Orthop.* 2005;29:101-4.