

# Double Meckel's Diverticulum in a Boy

Quratulain Soomro, Sirajuddin Soomro, Sikandar Ali Mughal

## ABSTRACT

*Meckel's diverticulum is the remnant of vitello-intestinal duct and the most common congenital anomaly of gastrointestinal tract. Usually it is a single diverticulum. Finding a duplication of Meckel's diverticulum is an extremely rare incident. We report a ten year old boy who presented with abdominal pain in whom, at exploration double Meckel's diverticulum was found.*

*Key words* Intestinal duplication, Meckel's diverticulum, Vitello-intestinal duct.

## INTRODUCTION:

Meckel's diverticulum named after German anatomic pathologist Johann Friedrich Meckel, is the most common congenital anomaly of the gastrointestinal tract that affects 2% of general population.<sup>1</sup> During early fetal development, the fetal midgut is attached to the yolk sac for nutrition via the yolk stalk or vitelline duct, and failure of the most proximal portion of the duct to regress during 5-7<sup>th</sup> week of embryological development results in Meckel's diverticulum.<sup>2</sup> Meckel's diverticulum is 3-5 cms long and located on antimesenteric border of ileum. Most of the Meckel's diverticulae remain silent. Finding a duplication of Meckel's diverticulum is extremely rare. One such case is reported.

## CASE REPORT:

A 10 year old boy presented to ER with three days history of severe diffuse abdominal pain, bilious vomiting and fever. Patient had no prior history of such pains. On general physical examination, patient was found febrile (102<sup>o</sup>F) having tachycardia (120/min) and restless. His abdominal examination revealed fullness with generalized tenderness, and absent bowel sounds. Rectal examination was unremarkable. Plain abdominal radiograph showed multiple air fluid levels and distended bowel loops, suggestive of intestinal obstruction.

After initial resuscitation, the patient was taken to OR for exploration. At laparotomy, the omentum was found adherent to ileal loops and cecum. Separation

of omentum exposed a perforated Meckel's diverticulum, which was broad based, 2 cm in size, and located 12 cm proximal to ileo-cecal junction, covered with fibrin flakes. Diverticulectomy with suture closure of the base was done. Inspection of the rest the intestine revealed another similar diverticulum situated approximately 30 cm proximal to the first one, 2.5 cm in length with wide base like the first one. The second diverticulum had its own blood supply and was located along antimesenteric border of ileum about 42cm proximal to ileo-cecal junction (Figure 1). This diverticulum was also excised and the defect repaired. The postoperative course was uneventful. The histopathology of both specimens identified them to be true ileal diverticulae, and double Meckel's diverticulae by definition.

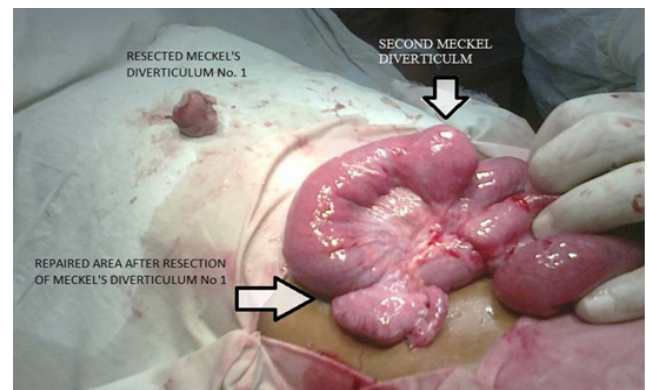


Fig 1: Intraoperative picture of double Meckel's diverticulum

## DISCUSSION:

Meckel's diverticulum possesses all the three layers of wall of intestine and it is supplied by omphalomesenteric branch of superior mesenteric artery. It can become symptomatic when gets inflamed or obstructed.<sup>4</sup> A person with Meckel's diverticulum has a 4-6% lifetime risk of developing complications.

## Correspondence:

Dr. Sirajuddin Soomro  
Department of Paediatric Surgery  
Chandka Medical College Hospital  
Larkana  
E mail: soomrosiraj@yahoo.com

When symptomatic it may present as diverticulitis, intestinal obstruction, lower gastrointestinal bleeding, intussusception and/or peritonitis.<sup>2, 4</sup>

Our patient presented with signs and symptoms of peritonitis as he developed perforated Meckel's diverticulum which was walled off by the momentum and also developed fibrinous adhesive obstruction. Meckel's diverticulum when complicated is hardly diagnosed preoperatively. Treatment options for Meckel's diverticulum are open or laparoscopic diverticulectomy / wedge resection and anastomosis.<sup>1,4</sup>

Finding a double Meckel's diverticulum during surgery is an extremely rare event. International literature is very scarce about duplication of Meckel's diverticulum. The first case of duplication of Meckel's diverticulum was reported by Albu and his colleagues in 1992.<sup>5</sup> Subsequently other reports appear in literature.<sup>6-9</sup> Blando-Ramirez JS and others found only nine reports of duplication of Meckel's diverticulum in the international literature before the addition of their case as 10<sup>th</sup>.<sup>3</sup> In our case both the diverticulae were within 42 cm of ileo-cecal junction and situated on the antimesenteric border of ileum. Histopathology also confirmed the true diverticular nature of the resected specimens.

#### REFERENCES:

1. Snyder CL. Meckel Diverticulum: Pediatric Surgery by Coran AG, Caldamone A, Adzick N.S, Krummel TM, Laberge JM, Shamberger R. 7<sup>th</sup> edition. Elsevier.2012:1085-92.
2. Sharma RK, Jain VK. Emergency surgery for Meckel's diverticulum World J Em Surg. 2008;3:27.
3. Blando-Ramírez JS, Ocadiz-Carrasco J, Gutiérrez-Padilla RA, Vicencio-Tovar A, Ricardez-García JA. Meckel's diverticulum duplication. Case report and literature review. Cir Cir. 2014;82:332-7.
4. Ghritlaharey RK, Budhwani KS, Shrivastava DK, Srivastava J. Meckel's diverticulum and patent vitello-intestinal duct in children. A review of 11 years of experience with 46 cases. J Clin Diag Res. 2011;5:689-93.
5. Albu E, Solomon L, Shah AK, Murthy RM, Gerst PH. Double Meckel's diverticulum. South Med J. 1992;85:1142-4.

6. Losanoff JE, Kjossev KT. Meckel's diverticulum duplication. Case report. S Afr J Surg. 2000;38:61-2.
7. Urakawa M, Ikeno T, Arai T, Natori K, Miyamoto H, Kawaguchi K. Meckel's diverticulum duplication revealed by acute operation of ileus: A case report. Nihon Shokakibyo Gakkai Zasshi. 2009;106:542-5.
8. Fajardo R, Cuevas V, Fuentes J. Double Meckel's diverticulum: laparoscopic resection. Rev Colomb Cir. 2011;26:2.
9. Emre A, Akbulut S, Yilmaz M, Kanlioz M. Double Meckel's diverticulum presenting as acute appendicitis: A case report and literature review. J Emerg Med. 2013;44:321-4.