

Biliary Ascariasis- Atypical Infestation of *Ascaris Lumbricoides*

Mariam Asif, Khalid Rashid, Aisha Siddiqui, Syed Sagheer Hussain Shah

ABSTRACT

Ascaris lumbricoides is the most frequent parasitic infestation in developing countries. Its usual habitat is small intestine. The less frequent sites are biliary tree, gall bladder, appendix and pancreas. This is a report of 36 year old woman who presented with the symptoms of acute cholangitis in whom at endoscopic retrograde cholangiopancreatography, worm was removed from bile duct through duodenal papilla.

Key words Biliary ascariasis, Cholangitis, ERCP.

INTRODUCTION:

Infestation with intestinal helminth, the *Ascaris lumbricoides*, can present in many ways.¹⁻³ In endemic areas, 30% of adults are affected.⁴ *Ascaris lumbricoides* can lead to cholangitis by invading the biliary tree through ampulla of Vater and presents as fever and jaundice. It can cause a variety of complications such as cholangitis, liver abscesses, choledocholithiasis and pancreatitis.^{2,3} We report a female patient with the less frequent presentation of biliary ascariasis.

CASE REPORT:

A 36 year old female patient presented to the clinic with two months history of right upper abdominal pain associated with high grade fever, jaundice and vomiting for 5 days. Fever was associated with rigors and chills. Patient was admitted for further workup and management. Physical examination revealed pallor, dehydration and jaundice. Body temperature was 102° F, pulse 110/min, blood pressure 130/90 mmHg and respiratory rate 24 breaths/min.

On abdominal examination, tenderness and guarding was present in right hypochondrium. Liver and spleen were not palpable. Investigations showed hemoglobin 9.3 g/dL, WBC 28.5x10⁹ cells/L, platelets 180 x 10⁹/L, urea 10.6 mmol/L and creatinine 177 µmol/L. Liver function tests were deranged as total serum bilirubin was 623 µmol/L, SGPT 167 U/L, SGOT 160 U/L, gamma-GT 348 U/L, alkaline phosphatase 989 U/L.

Correspondence:

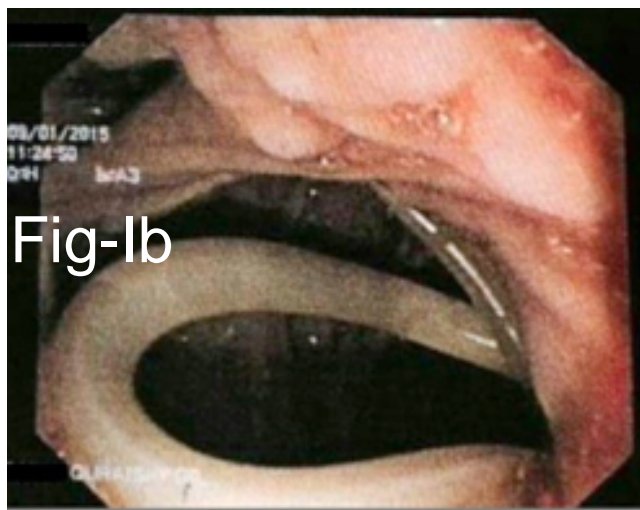
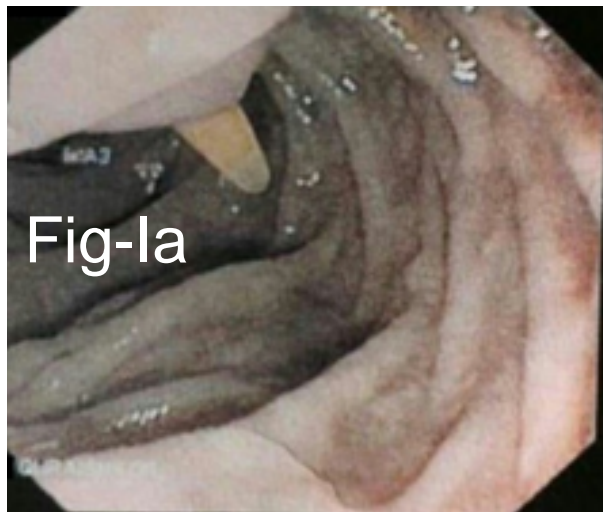Dr. Khalid Rashid
Department of Surgery
JPMC, Karachi
Email: dr.khalidrashid@hotmail.com

Abdominal ultrasound showed enlarged liver with coarse texture, enlarged and distended gall bladder. There was dilation of common bile duct (CBD), up to 1.1 cm. On MRCP, gall bladder appeared to be normal and no shadow signal was observed to suggest mass or stone. There was prominent CBD measured 8 mm. An elongated shaped calculus like shadow, measuring 8.5mm x 9mm was seen within distal CBD just proximal to ampulla. Calculus measured 1.4 cm in longitudinal dimension and pancreatic duct was prominent, measuring around 2.4 mm. Initial diagnosis was, cholangitis due to stones in the bile duct. After stabilizing the patient, ERCP was done. It revealed *Ascaris lumbricoides* in the common bile duct that was cause of cholangitis. The worm was removed at ERCP (Figure I). Later on patient was dewormed with albendazole. Patient made an uneventful recovery.

DISCUSSION:

Ascaris can have serious manifestations while housing in the biliary tract. It can be fatal when presents with obstructive cholangitis, septicemia and liver abscesses.^{1,5} *Ascaris lumbricoides* are common in people living in tropical and subtropical areas due to poor hygiene and unhealthy environment. The jejunum is main location of these worms. These parasites may enter duodenum due to increased pressure created by large number of worms in jejunum. Parasites have a great power to pass through small openings. In duodenum, worms may pass through the orifice of ampulla and invade bile and hepatic ducts, eventually causing hepato-biliary ascariasis.

The most common clinical presentation of biliary ascariasis is pain which is more constant than colic.⁶ Infrequently, it can present with fever, nausea



(Fig 1: a & b). Endoscopic view of the worm.

2. Alam S, Mustafa G, Ahmad N, Khan M. Presentation and endoscopic management of biliary Ascariasis. *Southeast Asian J Trop Med Public Health.* 2007; 38:631-5.
3. Hussain S, Islam A, Ahmad S, Mohsen A, Khanam F. Biliary Ascariasis: An experience of 47 cases. *Bangladesh Med Coll J.* 2010;15:59-62.
4. Rather A, Salati SA. Rare presentation of biliary ascariasis. *J Coll Physicians Surg Pakistan.* 2010;20:616-7.
5. Andrade Júnior DRD, Karam JA, Warth MDPTN, Marca AFD, Jukemura J, Machado MCC, et al. Massive infestation by *Ascaris lumbricoides* of the biliary tract: report of a successfully treated case. *Revista do Instituto de Medicina Tropical de São Paulo.* 1992;34:71-5.
6. Sivakumar K, Varkey S, George MP, Rajendran S, Hema R. Biliary ascariasis. *J Indian Assoc Pediatr Surg.* 2007;12:85-8.
7. Singal KK, Singal N, Gupta P, Jain N, Talwar N, Cheema YS. Ascariasis in the gall bladder - A rare case. *Bangladesh J Med Sci.* 2014;13:343-4.

jaundice and vomiting. Our patient presented with same complaints. Abdominal ultrasonography is considered the preferred method of diagnosis for biliary ascariasis.⁶ Computed tomography and magnetic resonance imaging are also used for diagnostic purposes. On MRCP in our patient worm was reported as stone. ERCP has both diagnostic and therapeutic roles in biliary ascariasis and same was the case in our patient.⁷ A high level of suspicion because of endemic area and conformation by radiological investigations, play an important role in the timely diagnosis of this disease as there can be serious complications if diagnosis is delayed.

REFERENCES:

1. Said A, Muhammad A, Maysoon M, Masood UR, Amer AJ. Biliary ascariasis leading to choledocholithiasis, cholangitis, hepatic abscesses and gram negative septicemia. *Anaesth Pain Intens Care.* 2012;16:186-8.