

# Thyroidectomy of Massive Goiter Always A Surgical Challenge

N.S.Sharma, Surbhi Kudyar, Aneet Chawla

## ABSTRACT

*Multinodular goiter is a relatively common thyroid disorder with a marked female preponderance. Most of these goiters weigh less than 100 grams with a few especially in endemic areas as marked by WHO, weighing approximately 200-250 grams and very rarely weighing more than 450 grams pose a challenge for an operating surgeon. Herein we report removal of giant goiter in a 60 year old female.*

*Key words* Giant goiter, Thyroidectomy, Female.

## INTRODUCTION:

It is estimated that nodular goiter affects 5% of general population.<sup>1</sup> The usual goiter growth ratio is estimated at 10 to 20% per year, though high individual variability in the clinical course makes it difficult to predict whether the goiter size will remain stable or whether dynamic thyroid growth will lead to its rapid progress warranting surgical intervention.<sup>2</sup> Most of these goiters are of moderate size being less than 100 grams.<sup>3</sup> Glands weighing approximately 450 grams or more are extremely unusual and often result as a consequence of ignorance, neglect, lack of inadequate medical facility, fear of undergoing surgery, or due to an unusually rapid growth.<sup>4</sup> The removal of such goiters remains a challenge.

## CASE REPORT:

### Case-1

A 60 year old female presented with a massively enlarged goiter of more than 32 years duration. Patient recently presented with history of stridor on exertion and dysphagia with dysphonia. Patient was on tablet thyroxine, 100 mcg twice daily and was taking this treatment for the last 32 years. On examination the mass measured 21 cms x 18 cms occupying most of the neck (Fig I). The lower border could not be felt. The complete blood picture and the thyroid function tests were within normal limits. About 72 hours before surgery thyroxine was stopped. Fresh blood sample was sent for thyroid function and before the surgery T<sub>3</sub> level was

1.64, T<sub>4</sub> level 8.63 and TSH level was 0.28. After an informed consent the patient was posted for near total thyroidectomy.

Flexible intubation was performed. After adequate extension of the neck supported by sand bag, the neck was explored using a 10-12 cms incision. After reflecting the subplatysmal skin flaps the thyroid gland was exposed by dividing the strap muscles as there was significant compression of internal jugular veins and carotid vessels and distortion and displacement of these structures (Fig II). The superior pedicle, multiple dilated veins, middle thyroid veins and inferior thyroid veins and inferior thyroid artery were carefully ligated on both sides. The recurrent laryngeal nerves and parathyroids were identified on both sides and preserved. The retrosternal extension of the goiter was delivered into the neck by gentle finger dissection and upward traction in the subcapsular plane. The tracheal cartilages were soft and weakened due to tracheomalacia so immediate tracheostomy was done. The postoperative period

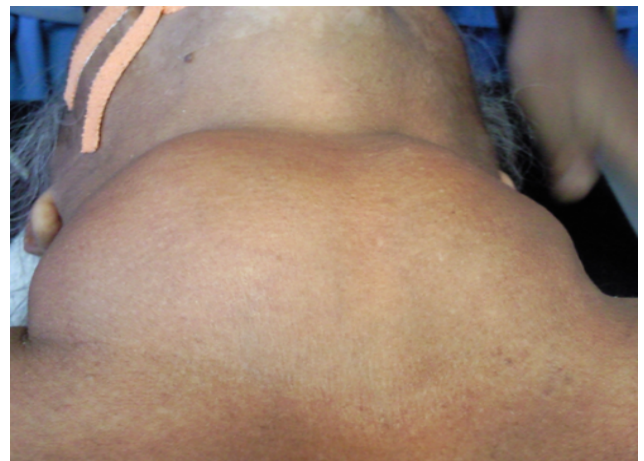


Fig I: Giant Goiter

## Correspondence:

Dr. Surbhi Kudyar  
Department of Surgery  
Maharishi Markandeshwar Institute of Medical Sciences  
and Research Mullana, Ambala, India  
E mail: skudyar@gmail.com

was uneventful. The histopathology was reported to be multinodular colloid goiter. The total weight of the excised gland was 482 grams (Figure III).

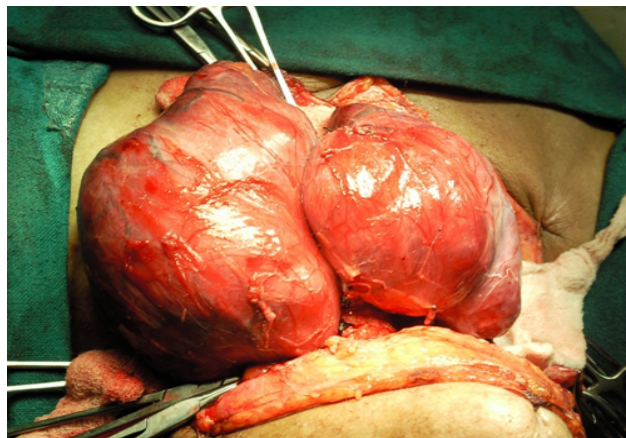


Fig II: Intraoperative view of enlarged thyroid

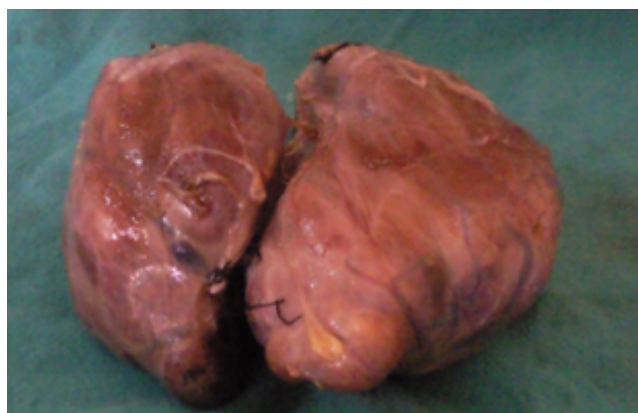


Fig III: Goiter removed at surgery weighing 482 grams

#### DISCUSSION:

Thyroidectomy for massively enlarged goiter could be technically challenging particularly when the goiter is approximately 500 grams. The specific problem associated with them are difficulty in securing airway, injury to the recurrent laryngeal nerve, esophagus and parathyroid. Moreover there is an increased possible association of tracheomalacia, tracheal compression by the massively enlarged goiter.<sup>4</sup>

Surgeon must be careful in recognizing tracheomalacia on the operating table before extubation. There is no single fool proof criteria for confirming a diagnosis of tracheomalacia. However, for intraoperative diagnosis of tracheomalacia following criteria can be taken: (1) Soft and floppy trachea on palpation by the surgeon at the end of thyroidectomy. However because of splinting effect of endotracheal tube in situ, it may be difficult to appreciate a soft trachea. We therefore, ask the anesthesiologist to gradually withdraw the tube

for a short distance and then feel the trachea without the tube in situ. This may also help the surgeon to recognize an obvious collapse of the tracheal wall. (2) Obstruction to spontaneous respiration during gradual withdrawal of ETT after thyroidectomy. (3) Difficulty in negotiating the suction catheter beyond the ETT after gradual withdrawal. (4) After closure of the wound tracheomalacia can be suspected (a) if there is absence of peritubal leak on deflation of ETT cuff, (b) Volume pressure loop on ventilator or (c) Development of respiratory stridor along with a falling hemoglobin oxygen saturation (SpO<sub>2</sub>) on pulse oximeter despite the administration of increasing FiO<sub>2</sub>. It is also important to rule out vocal cords palsy or glottis/subglottic edema which are more common causes of stridor.

Suggested methods of management of tracheomalacia are tracheostomy, prolonged intubation, tracheopexy, external splinting with Marlex mesh, and external miniplate fixation of tracheal cartilages and placement of a buttress or graft. It has been suggested that leaving the endotracheal tube in place for 24-48 hours postoperatively to serve as a splint before extubation in a controlled setting can be successful in many cases.<sup>5</sup> We preferred tracheostomy in our patient.

Thyroidectomy for a massively enlarged goiter especially is technically challenging. Airway management, integrity of adjacent structures as well as anticipating the possible complications should be considered as high priority. In spite of the technical challenges, surgery continues to be the best option particularly in experienced hands due to its distinct advantage of immediate effect and complete resolution of compressive symptoms.

#### REFERENCES:

1. Day TA, Chu A, Hoang KG. Multinodular Goiter. *Otolaryngologic Clin North Am.* 2003;36:35-54.
2. Berghout A, Wersinga WM, Drexhage HA, Smiths NJ, Touber JL. Comparison of placebo with L- thyroxine alone or with carbimazole for treatment of sporadic non toxic goiter. *Lancet.* 1990;336:8709. 193-7.
3. Gardiner KR, Russell CF. Thyroidectomy for large multinodular colloid goitre, *J Roy Coll Surg Edinb.* 1995; 40:367-70.
4. Harjit KD, Hisham AN. Large fungating thyroid cancers. a unique surgical challenge. *Asian J Surg.* 2005;28:48-51.

5. Agrawal A, Mishra AK, Gupta SK, Arshad F, Tripathi M, Singh PK. High incidence of tracheomalacia in long standing goiters : Experience from an endemic goiter region. World J Surg. 2007; 31:832-7.