

OMENTAL CAKING: A RARE BUT GRAVE SIGN IN PROGNOSIS OF CARCINOMA ENDOMETRIUM

KIRAN EJAZ, SAJJAD RAZA, WAQAR KASHIF

ABSTRACT

Peau d' orange abdomen clinically and omental caking on CT scan, are findings which often makes one think of critical disease. In our part of the world tuberculous (TB) peritonitis is one of the major causes of these signs. However, it can also be found in abdominal or pelvic malignancy. In this interesting case the patient suffered from carcinoma endometrium which was diagnosed at stage IV and had no organ involvement other than the greater omentum and the primary site.

Key words

Omental caking, Carcinoma endometrium, Peau d' orange abdomen.

INTRODUCTION:

According to the North American Association of Central Cancer, estimated new cases of uterine carcinoma in 2007 were 39,080 and the estimated deaths in same year 7,400.¹ Finding thick solid omental masses generally indicates advanced disease and may be evident on physical examination. The relative amount of ascites does not correlate with the omental pattern and diagnosis.²

CASE REPORT:

A 60 years old lady, a known case of stage IV carcinoma endometrium, type 2 respiratory failure and suspected pulmonary embolism presented to the emergency department with progressive shortness of breath for 3 days. She had been on home bi-level intermittent positive air pressure (BiPAP) and two liters of oxygen but her condition was not improving. On arrival she was not able to complete a single sentence. With her heavy built she was lying in a semi right lateral position and was not able to lay flat or sit up. Her physician had stopped her prophylactic oral warfarin two days prior from presentation.

Examination revealed pitting pedal edema. She had a GCS of 15/15. Vital signs showed hypotension with tachycardia

and O₂ saturation of 96% at 3 liters of O₂ with face mask. Her trachea was central and chest examination revealed unequal expansion with no air entry in the right middle and lower zones with resonant note at bilateral apices. Her abdomen was large protruded, with peau d' orange appearance in the central region. However, it was non-tender without any palpable visceromegaly. Shifting dullness was present and gut sounds were audible.

Her deranged serum values were an INR of 2.57, a leucocyte count of 13.9 and a creatinine of 1.2 mg %, otherwise rest were within normal limits. Blood gases showed that she was not retaining carbon dioxide and had a good acid base balance. Her radiological investigations revealed a bilateral mild to moderate pleural effusion with basal collapse, a magnified mediastinum and cardiac silhouette along with perihilar vascular congestion suggestive of pulmonary edema.

The CT abdomen and pelvis with I/V contrast done for her metastatic workup showed bilateral pleural effusion, with evidence of thickening of omentum beneath the anterior abdominal wall. Findings were consistent with omental caking. A bulky uterus with thickened endometrium and body wall edema were also seen. There was no evidence of lymphadenopathy and Liver, lungs and bones had no signs of metastasis (Fig-1).

Correspondence:

Dr. Kiran Ejaz,
Research Associate,
Aga Khan University Hospital
Karachi

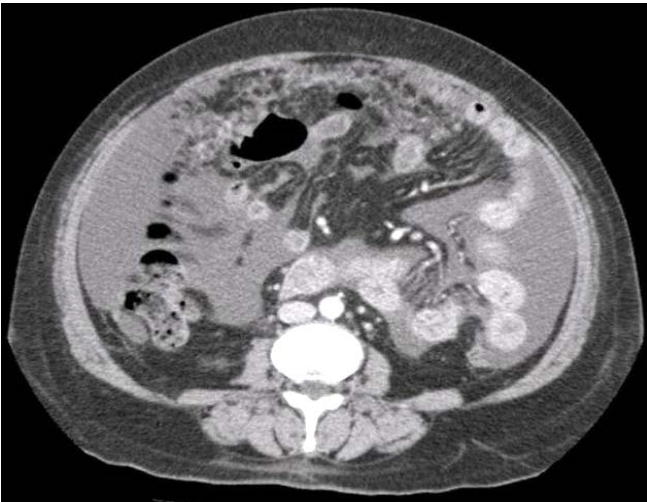


Figure 1: Radiological findings of omental caking

She was resuscitated with a liter of saline. Her ultrasound guided right sided pleural tap yielded a liter of exudative fluid. Her left sided pleural effusion was non tap-able. An ascitic catheter was placed to drain three liters of ascitic exudative fluid. She was relieved of her symptoms and, after her pleural and ascitic tap, was discharged back home. Since her tumor was unresectable, she was advised hormonal therapy as an out patient.

Later, her pleural fluid cytology was reported to have an immunohistochemical profile favoring female genital tract primary tumor, with tumour markers Ber-EP4, Cytokeratin 7 and CA-125 coming positive. She was diagnosed as metastatic adenocarcinoma of endometrium.

DISCUSSION:

The greater omentum is an extension of the anterior and posterior visceral peritoneum. As noted in our case, very few cases have been reported of carcinoma endometrium with involvement of the omentum and presentation of omental caking. Omental pathology most often appears as nodular or omental caking. Metastatic disease is a cause of omental abnormality, but most commonly a smudged pattern is seen,^{2,3} unlike our patients' omentum, that appeared scrolled upwards. Others have documented omental caking in tuberculous peritonitis.

In a study involving the CT findings of omental pathology only 17 out of 46 patients (37%) showed omental caking due to malignancies other than carcinoma endometrium. No benign inflammatory lesions are reported to show this finding.² In 1985, Rubesin SE, Levine MS, presented 7 cases of pelvic malignancy with omental pathologies, only one case was of endometrium malignancy.⁴ A retrospective study by Jin H and Min PQ, in People's Republic of China reviewed CT scans of 34 patients known to have gastric malignancies. They found omental caking in CTs of only two patients (6%).⁵ No study involving female genital tract

cancers have been conducted as yet.

Direct imaging of omentum is not possible with conventional radiographic studies Indirect evidence of omental pathology is suggested by plain radiography, ultrasound and barium studies. However, the fibro fatty components of the greater omentum are routinely identified on CT through the upper abdomen as a fat attenuation area anterior to the transverse colon.² In 1986, a similar study was done by et al, to see the CT presentations of omental pathology. The normal omentum is identified on CT of the abdomen as a homogeneous fat density anterior to the transverse colon. Four distinct patterns of omental pathology were identified as (a) omental caking, (b) finely infiltrated fat with a "smudged" appearance, (c) cystic masses, and (d) discrete nodules.^{2,3} Rarely, a T-cell lymphoproliferative process may mimic primary peritoneal carcinomatosis, clinically suggested by a presentation in CT imaging of omental caking with bilateral massive loculated effusions in a patient without lymphadenopathy or splenomegaly.⁶ CT allows detection and characterization of even unsuspected omental disease on routine studies. Although the pattern of omental involvement alone is relatively nonspecific, in only one patient this was the sole CT abnormality.² CT provides the most reliable radiographic technique to routinely evaluate omental pathology.^{2,4}

Treatment option for such patient includes chemotherapy. Radiotherapy has its own negative aspects. As proven in a case of a Chinese lady with ovarian cancer and omental caking, four cycles of chemotherapy, had a near complete resolution of omental metastases. This was demonstrated on both CT and laparotomy.⁷ Our patient was also put on chemotherapy in a hope to gain some palliation.

REFERENCES:

1. Jemal A, Siegel R, Ward E, Murray T, Xu J, Thun MJ. Cancer Statistics, Ca Cancer J Clin. 2007; 57:43-66.
2. Cooper C, Jeffrey RB, Silverman PM, Federle MP, Chun GH. Computed tomography of omental pathology. J Comput Assist Tomogr. 1986;10:62-6.
3. Silverman PM. The subperitoneal space: mechanisms of tumor spread in the peritoneal cavity, mesentery, and omentum. Cancer Imaging. 2003;4:25-9.
4. Rubesin SE, Levine MS. Omental cakes: colonic involvement by omental metastases. Radiology. 1985;154:593-6.

5. Jin H, Min PQ. Computed tomography of gastrocolic ligament: involvement in malignant tumors of the stomach. *Abdom Imaging*. 2007;32:59-65.
6. Siderits R, Godyn J, Tufankjian D, Ouattara O. T cell lymphoproliferative disorder of hand-mirror cell morphology presenting in an eosinophilic loculated peritoneal effusion, with omental "caking". *Cyto J*. 2006;8:13.
7. Helpert C, Peh WC, Ng TY. Clinics in diagnostic imaging. Omental caking due to ovarian carcinoma. *Singapore Med J*. 1995;36:667-9.